Scientific Excellence • Resource Protection & Conservation • Benefits for Canadians
Excellence scientifique • Protection et conservation des ressources • Bénéfices aux Canadiens

Guide to microscopic and macroscopic identification of the sexual maturity stages of the Atlantic herring (*Clupea harengus harengus* L.)

Jean Landry and Ian H McQuinn

Fisheries Research Division
Department of Fisheries and Oceans
Maurice Lamontagne Institute
P O Box 1000, 850 route de la Mer
Mont-Joli, Quebec G5H 3Z4

December 1988

Canadian Technical Report of Fisheries and Aquatic Sciences

No 1655

Fisheries and Oceans
Pêches et Océans

Canada

Canadian Technical Report of Fisheries and Aquatic Sciences

Technical reports contain scientific and technical information that contributes to existing knowledge but which is not normally appropriate for primary literature. Technical reports are directed primarily toward a worldwide audience and have an international distribution. No restriction is placed on subject matter and the series reflects the broad interests and policies of the Department of Fisheries and Oceans, namely, fisheries and aquatic sciences.

Technical reports may be cited as full publications. The correct citation appears above the abstract of each report. Each report is abstracted in *Aquatic Sciences and Fisheries Abstracts* and indexed in the Department's annual index to scientific and technical publications.

Numbers 1–456 in this series were issued as Technical Reports of the Fisheries Research Board of Canada. Numbers 457–714 were issued as Department of the Environment, Fisheries and Marine Service, Research and Development Directorate Technical Reports. Numbers 715–924 were issued as Department of Fisheries and the Environment, Fisheries and Marine Service Technical Reports. The current series name was changed with report number 925.

Technical reports are produced regionally but are numbered nationally. Requests for individual reports will be filled by the issuing establishment listed on the front cover and title page. Out-of-stock reports will be supplied for a fee by commercial agents.

Rapport technique canadien des sciences halieutiques et aquatiques

Les rapports techniques contiennent des renseignements scientifiques et techniques qui constituent une contribution aux connaissances actuelles, mais qui ne sont pas normalement appropriés pour la publication dans un journal scientifique. Les rapports techniques sont destinés essentiellement à un public international et ils sont distribués à cet échelon. Il n'y a aucune restriction quant au sujet; de fait, la série reflète la vaste gamme des intérêts et des politiques du ministère des Pêches et des Océans, c'est-à-dire les sciences halieutiques et aquatiques.

Les rapports techniques peuvent être cités comme des publications complètes. Le titre exact paraît au-dessus du résumé de chaque rapport. Les rapports techniques sont résumés dans la revue *Résumés des sciences aquatiques et halieutiques*, et ils sont classés dans l'index annual des publications scientifiques et techniques du Ministère.

Les numéros 1 à 456 de cette série ont été publiés à titre de rapports techniques de l'Office des recherches sur les pêcheries du Canada. Les numéros 457 à 714 sont parus à titre de rapports techniques de la Direction générale de la recherche et du développement, Service des pêches et de la mer, ministère de l'Environnement. Les numéros 715 à 924 ont été publiés à titre de rapports techniques du Service des pêches et de la mer, ministère des Pêches et de l'Environnement. Le nom actuel de la série a été établi lors de la parution du numéro 925.

Les rapports techniques sont produits à l'échelon régional, mais numérotés à l'échelon national. Les demandes de rapports seront satisfaites par l'établissement auteur dont le nom figure sur la couverture et la page du titre. Les rapports épuisés seront fournis contre rétribution par des agents commerciaux.

Canadian Technical Report of
Fisheries and Aquatic Sciences
No 1655

December 1988

Guide to microscopic and macroscopic identification of the sexual maturity stages of the Atlantic herring (*Clupea harengus harengus* L)

Jean Landry and Ian H McQuinn

Fisheries Research Division
Department of Fisheries and Oceans
Maurice Lamontagne Institute
P O Box 1000
850, route de la Mer
MONT-JOLI, Quebec
G5H 3Z4

Department of Supply and Services Canada 1988
Catalogue No 97-6/1655E ISSN 0706-6457

This publication is also available in french and may be cited as follows:

Landry, Jean and Ian H McQuinn, 1988. Guide to microscopic and macroscopic identification of the sexual maturity stages of the Atlantic herring (Clupea harengus harengus L). Can Tech Rep Fish Aquat Sci 1655: 71 p.

TABLE OF CONTENTS

	Page
LIST OF APPENDICES	iv
RESUME/ABSTRACT	v
PREFACE	vi
INTRODUCTION	1
Macroscopic identification of sexual maturity	1
Microscopic identification of sexual maturity	2
Objectives of the study	2
MATERIAL AND METHODS	3
Sampling zone and period	3
Histological sections	3
Photographs and descriptions of the gonads	3
Outline of the study	4
Presentation of the guide to identification	4
EVOLUTION OF OVARIAN MATURATION	4
Histological classification	4
Macroscopic classification	12
Discussion	15
EVOLUTION OF TESTICULAR MATURATION	18
Histological classification	18
Macroscopic classification	25
Discussion	26
CONCLUSION	28
REFERENCES	29
PLATES	32

LIST OF APPENDICES

Appendices		Page
1	Macroscopic classification of the sexual maturity stages of the herring used by the Canadian Atlantic Fisheries Scientific advisory Committee (CAFSAC)	64
2	Histological criteria defining each maturity stage	66
3	Macroscopic criteria to be given priority in assigning sexual maturity stage	70

RESUME

Landry, Jean et Ian H McQuinn. 1988. Guide d'identification microscopique et macroscopique des stades de maturité sexuelle du hareng de l'Atlantique (Clupea harengus harengus L). Rapp tech can sci halieut aquat 1655: 71 p.

Des critères d'identification histologiques précis ont été associés à chacun des huit stades macroscopiques de maturité sexuelle du hareng de l'Atlantique (Clupea harengus harengus L) de la classification adoptée par le Comité Scientifique Consultatif des Pêches Canadiennes dans l'Atlantique (CSCPCA). L'étude histologique a aussi permis de subdiviser davantage le cycle de développement des gonades du hareng (11 stades chez les mâles et 12 chez les femelles) et d'apporter des améliorations à la clé macroscopique. Notamment, la coloration des gonades ne doit être utilisée, même avec des échantillons frais, que pour séparer le début du stade VIII du stade II (à partir des teintes rouge-vin plus prononcées au stade VIII). Chez les femelles, la distinction des stades VIII et III doit être faite d'abord à partir de la possibilité de distinguer les oeufs à l'oeil nu au stade III. La longeur des gonades par rapport à celle de la cavité coelomique a été ajoutée (ou corrigée dans le cas du stade IV) aux descriptions existantes. La priorité à accorder à chaque critère a été établie plus clairement: le plus souvent, la définition du stade de maturité repose d'abord sur la largeur et la longeur relative des gonades. La définition de critères prioritaires ne diminue généralement pas les imprécisions de la clé macroscopique, mais offre la possibilité d'en uniformiser l'utilisation.

ABSTRACT

Landry, Jean and Ian H McQuinn. 1988. Guide to microscopic and macroscopic identification of the sexual maturity stages of the Atlantic herring (Clupea harengus harengus L). Can Tech Rep Fish Aquat Sci 1655: 71 p.

Precise histological identification criteria associated with each of the eight macroscopic sexual maturity stages of Atlantic herring (Clupea harengus harengus L) from the Canadian Atlantic Fisheries Scientific Advisory Committee (CAFSAC) classification key are described. The histological study also permitted a more detailed subdivision of the gonadal development cycle of herring (11 stages for males, 12 for females), and enabled the incorporation of several improvements to the macroscopic staging key. Notably, gonad colour should only be used, even with fresh samples, to separate the beginning of stage VIII from stage II (the wine red tint being more pronounced in stage VIII). For females, the distinction between stages VIII and III must be made foremost from the visibility of the eggs with the naked eye in stage III. Gonad length relative to that of the coelomic cavity was added (or corrected in the case of stage IV) to the existing descriptions. The priority accorded to each criterion was more clearly established, maturity stage identification most often resting principally on the relative width and length of the gonads. However, the establishment of criteria priorities does not generally diminish the imprecisions of the macroscopic key, but rather offers the possibility of standardizing its utilization.

PREFACE

This study was inspired largely by the histological studies on the sexual maturity of the herring (Clupea harengus harengus L) performed by Bowers and Holliday (1961) and Polder (1961). The present study differs in that it specifies more clearly the microscopic and macroscopic criteria to be used in classifying each of the stages of sexual maturity in the herring. These more detailed descriptions were made necessary by the variety of interpretations open to different individuals in connection with the same classification. The numerous photographs of gonads included in this study will facilitate a better understanding of the gonad maturation process in the herring throughout the reproductive cycle, and will thus allow more uniform application of this classification.

The sexual maturity classification used in this study is compatible with that adopted by the International Council for the Exploration of the Sea (ICES) and by the Canadian Atlantic Fisheries Scientific Advisory Committee (CAFSAC). This classification guide can thus serve as a reference tool for a wide range of individuals wishing to use maturity stage in research studies on the herring.

INTRODUCTION

MACROSCOPIC IDENTIFICATION OF SEXUAL MATURITY

Study of the reproductive cycle of the herring (Clupea harengus harengus L) can clarify a number of important aspects in the life cycle of this species. For example, a number of phenomena which may affect catches of this fish, such as herring concentrations prior to spawning, migrations and spawning itself, may be related to the reproductive cycle (Naumov, 1956). Sexual maturity stage is thus a factor commonly used in many research studies on the herring.

The first to define a guide to the classification of herring gonad maturity stages was Heincke, in 1898 (Naumov, 1956). His classification was based on macroscopic criteria such as colour and firmness of the gonads, and the visibility of the eggs to the naked eye or with a magnifying glass. A number of classification guides were subsequently produced on the basis of modifications to Heincke's work. Each claimed to be more complete than the last, or simply served to adapt the key to other species of fish. Naumov (1956) has briefly reviewed the classifications which followed Heincke's. Among those developed for herring was that of Broch (1908), which used gonad size to define the various stages of maturity. Lea (1910) added gonad thickness to the Heincke key and Johansen (1924) introduced oocyte diameter to determine the maturity stage in females. Naumov (1956) himself produced a relatively detailed description of ovary maturity stages based on a number of existing classifications. In fact, as knowledge of the herring increased and the species was divided into smaller taxonomic units, it became necessary to establish a new classification (Naumov, 1956).

More recently, we have seen the development of the classification adopted by the International Council for the Exploration of the Sea (ICES), and later, with minor changes, by the Canadian Atlantic Fisheries Scientific Advisory Committee (CAFSAC - Appendix 1). This classification uses criteria similar to those established by Johansen. It divides the reproductive cycle of the herring into eight stages. Stages I and II are associated with virgin herring, while stages III to V correspond to the phase of rapid gonad growth. Spawning occurs at stage VI and is followed by a period of reconstruction, corresponding to stages VII and VIII. Finally, the gonads pass from stage VIII into stage III, thus initiating a new maturation cycle.

A number of serious problems with the macroscopic classification adopted by CAFSAC have been identified by Cleary et al. (1982). This classification is considered adequate for fresh fish only at the precise levels of development described in the classification. However, the criteria used are defined too vaguely to permit precise, objective classification of the various stages during transition periods. In addition, stages VIII and III are felt to be inadequately documented; the classification does not permit consideration of all possible variations, with the result that gonad weight must sometimes be used (by certain laboratories) to distinguish these two stages. Finally, the macroscopic key is considered inadequate for frozen samples, the state in which most samples are examined. The stages assigned on the basis of such samples differ widely from those established on the basis of fresh specimens; gonad colour, in particular, is seriously affected by freezing. All these problems leave room for a variety of interpretations by the different users of the CAFSAC classification, thus reducing the method's reliability.

The problems associated with the macroscopic classification may have an impact on one of the principal applications for which it is used by CAFSAC, the separation of Atlantic herring spawning groups in the Gulf of St. Lawrence. The stocks in this region consist primarily of spring and autumn spawners (Day, 1957) and are managed

independently. The method by which they are separated consists of predicting the probable spawning season for an individual on the basis of its maturity stage at the time it is caught (Cleary et al. 1982). This method is based on the observation of two principal spawning peaks, one in May-June and the other in August-September (Haegele and Schweigert, 1985), with the dividing point being established, by convention, at July 1 (Cleary et al. 1982). According to this method, an individual in stage V in May is considered a spring spawner, since it is assumed that it will spawn (stage VI) before July. In contrast, an individual in stage V in August is considered an autumn spawner. This method is based on an arbitrary estimate of the duration of each maturity stage and may be affected by the possibility that individuals from the two stocks can be at the same maturity stage at certain times of the year (Cleary et al. 1982). Moreover, the separation of the stocks may be flawed from the outset by the imprecisions associated with the macroscopic method of determining maturity stage. A histological study of the reproductive cycle of the herring has therefore been undertaken to permit further precision of the CAFSAC classification.

MICROSCOPIC IDENTIFICATION OF SEXUAL MATURITY

Microscopic description of gonad maturation in the herring from histological sections has already been undertaken by a number of researchers, including Williamson (1945), Naumov (1956), Polder (1961) and Bowers and Holliday (1961). These authors have described the general morphology of the gonads and the principal physiological changes associated with each macroscopic stage in the reproductive cycle of the herring, but in most cases without precisely defining the criteria selected to determine each maturity stage. In addition, these researchers have used macroscopic classifications other than those used by CAFSAC. This means that the histological and macroscopic descriptions which they have associated with each maturity stage cannot always be applied to the CAFSAC guide. For example, Naumov's classification (1956) divides the reproductive cycle of the herring into six stages, rather than eight. Those developed by Polder (1961) and Bowers and Holliday (1961) consist of eight stages, but provide little information on the transition period between stages VIII and III.

OBJECTIVES OF THE STUDY

The principal objective of this study was to use the histological method to make the improvements advocated by Cleary et al. (1982) in the CAFSAC macroscopic classification. Emphasis has been placed on increased documentation of the period of gonad reconstruction and on determination of the priority to be assigned to the various macroscopic criteria used in defining each maturity stage.

Secondly, we hoped to produce a reference tool for use at both the microscopic and macroscopic levels, one which could be consulted by a majority of individuals, and which, through clearly established criteria, would permit more uniform application. The histological criteria associated with each maturity stage should therefore be defined precisely in order to compensate for the lack of precision shown by previous studies in this area. These histological criteria should also be selected for compatibility with the CAFSAC key, in order to avoid creating a new classification.

Finally, the data relating to the histologically defined stages were to serve as the basis for another study, undertaken by McQuinn (1989). This study was designed to develop another method of separating the spawning groups on the basis of maturity stages determined indirectly by means of a gonadosomatic index. It was therefore decided to include the additional information provided by the histological method, by subdividing

(within the eight initial divisions) the reproductive cycle of the herring into a larger number of stages.

MATERIAL AND METHODS

SAMPLING AREA AND PERIOD

The samples were collected from the 1984 commercial gillnet fishery (mesh size 2.25 to 2.5 inches), along the Gaspé peninsula, off the region extending from Grande-Rivière to Anse-à-Beaufils (NAFO division 4T). These were random samples, stratified by length, collected on a weekly basis between the months of May and October. This sampling, performed in a study area frequented by both spawning groups, enabled us to follow the major portion of the maturation cycle of both stocks concerned. Only stages I and II (immature) were collected less frequently, since the commercial gillnet fishery was oriented primarily towards mature individuals.

HISTOLOGICAL SECTIONS

A total of 2149 histological sections were prepared. These covered the entire range of maturity stages found in both sexes and both spawning groups.

The histological sections were prepared from a fragment of tissue approximately 5 mm thick taken from the central portion of one of the gonads, with the exception of the gonads of certain juveniles (stage I and occasionally II), which were retained intact. This method made it possible, first, to avoid the bias which might have been created by the different levels of development from one end of the gonad to the other (Bruslé and Bruslé, 1983) and, secondly, to avoid improper fixation of overly thick fragments.

The gonad samples were fixed in Bouin's fluid for approximately 24 hours, then stored in 70% alcohol. According to our observations, the fixation period should not exceed 6 to 8 hours, in order to avoid hardening of the tissues, particularly in the case of mature ovaries. Hardening of this kind can cause the sections to crumble, thus making staging difficult, if not impossible. The problem of overfixation can be overcome by dipping the fragments of tissue in celloidin (Naumov, 1956), or in a mixture of 9 parts 60% alcohol to one part glycerin (Baker, 1950, as reported by Bowers and Holliday, 1961).

The fragments stored in alcohol were sent to a private firm (Les Laboratoires Bio-Recherche Ltée) for preparation of the histological sections. The sections were 5 to 7 µm thick, embedded in paraffin and stained with hematoxylin and eosin.

PHOTOGRAPHS AND DESCRIPTIONS OF THE GONADS

A total of 330 gonads were photographed and described in detail, before being preserved for histological sectioning. The specimens selected represented all the variations encountered within each maturity stage. The observations noted corresponded generally to the criteria used in the CAFSAC macroscopic classification. These criteria were gonad width, length in relation to that of the body cavity, volume (100% of the body cavity or less), colour, and characteristics of the eggs. Gonad width was determined by measuring the gonads at two different locations: at the widest point (usually the central portion) and approximately two cm from the posterior end. They were measured on their widest surface, that is, on the basis of their position in the body cavity of the fish. The width was measured at two locations to take into account changes in gonad shape from one stage to another. The results of these measurements are not based, however, on any statistical test and must not be considered more than

simple indications. The same is true of the information relating to gonad volume, or length in relation to that of the body cavity, which is based not on precise measurements but merely on visual estimations.

The photographs and macroscopic descriptions of each gonad were subsequently compared to the corresponding histological sections. This permitted comparison of gonad development as indicated by the histological data and by the CAFSAC key. Of the histological characteristics studied, only mean oocyte diameter was quantified. However, this information was obtained from only a small number of measurements, performed on a number of oocytes considered representative of the maturity stage in terms of diameter. In addition, the measurements were taken in only one portion of the ovary (central portion).

OUTLINE OF THE STUDY

The definition of histological criteria compatible with the eight maturity stages described in the CAFSAC macroscopic classification, and the improvements to this classification, were performed in the following steps:

1. Microscopic analysis of changes in the gonads during their maturation cycle from the histological sections, complemented by information from the literature.

2. Identification of the principal histological changes suitable for use as objective criteria for the division of the reproductive cycle into precise stages.

3. Selection, from among the histological criteria deemed to be objective, of those permitting a classification of the maturity stages compatible with that of CAFSAC, and those permitting more detailed subdivision of certain maturity stages. This initial comparison with the CAFSAC classification was more or less approximate and was designed to avoid excessive discrepancies between the two methods. For example, we did not want the histologically defined stage III to correspond to CAFSAC stage V.

4. Final classification of the maturity stages on the basis of the selected histological criteria and new comparison with the macroscopic characteristics of the CAFSAC key. This second comparison was designed to assess the precision of the parameters used in the CAFSAC key and to define their relative importance in the identification of each stage.

PRESENTATION OF THE GUIDE TO IDENTIFICATION

This identification guide presents detailed microscopic and macroscopic descriptions for each sex and each maturity stage. The microscopic analysis of each of the stages includes two parts: a detailed description of the structures observed and a summary of the principal identification criteria selected. The macroscopic analysis is presented by establishing links with the microscopic descriptions. This makes it easier to assess the relevance of the criteria used in the field and to identify the improvements to be made to the CAFSAC key.

EVOLUTION OF OVARIAN MATURATION

HISTOLOGICAL CLASSIFICATION

Stage I

Stage I corresponds to the organization of the connective tissue and of the vascular system, and the beginning of production of a line of oocytes in the gonad. The growth of the ovary at this point is related primarily to an increase in the number of oocytes.

Organization of the connective tissue:

The infrastructure of the ovary consists of a wall from which a series of bands of connective tissue develop, extending across the gonad and acting as supports for the germ cells (Figure 1).

The wall consists of an external membrane, or epithelium, below which develops a thicker layer, consisting primarily of smooth muscle fibres and collagen fibres (Naumov, 1956; Polder, 1961). In stage I, the development of the wall may appear incomplete; at some points, the inner layer is developed and may be as much as 30 µm thick, while in other areas, the wall consists of only an external membrane (Figure 2).

The bands of connective tissue extend from the wall for the entire length of the gonad and are oriented perpendicular to its axis (Figure 1). Because of their orientation, these bands are more difficult to observe in transverse section (Figure 2) than in longitudinal section (Figure 3). The germ cells are found along these bands, in association with connective tissue, giving the ovary a more pronounced lamellar structure in stage I (longitudinal section) than in the later stages.

Vascularization

At the beginning of stage I, the vascularization of the ovary is very simple, consisting primarily of one vein and one artery running the full length of the gonad (Figure 1). By the end of this stage, a series of ramifications may extend throughout the gonad.

Germ cells:

The germ cells represent the basic structure used to identify the maturity stages. Thus, each stage is characterized by the passage of these cells to a given level of development. Stage I represents the period during which a line of oocytes is produced from the divisions and transformations undergone by a number of root germ cells, described as "primary germ cells" by Bowers and Holliday (1961). These authors also mention the existence of an intermediate stage preceding that of the oocytes, and known as oogonia. These are described as large circular cells, 10 to 14 µm in diameter, with a nucleolus located in the centre of the nucleus and connected to the periphery by filaments of chromatin. This description corresponds to the type of germ cell shown in Figure 4.

Passage from the oogonium to the oocyte stage is accompanied by growth of the nucleus and cytoplasm and by a rearrangement of the nucleus (Bowers and Holliday, 1961). The nucleoli of the oocytes are thus located around the periphery of the nucleus and their cytoplasm is much darker in colour than that of the oogonia (Figure 5). The oocytes may be approximately 130 µm in diameter by the end of stage I.

Follicle:

The follicle is the structure which surrounds the oocyte during its maturation. It plays the vital role of intermediary in the exchanges of material used in vitellogenesis occurring between the circulatory system and the cell (Naumov, 1956; Bowers and Holliday, 1961; Polder, 1961).

The only visible follicular layer in stage I is the theca (Figure 5). The theca represents the epithelium, or "wall", of the follicle, through which the blood vessels supplying the oocytes pass. It can be observed very early in stage I, when oocyte growth begins.

Identification criteria used:

The criteria considered of primary importance in the identification of stage I are as follows (Figures 2 to 5):

1. The principal phase of oocyte maturation has not yet begun; the oocytes are dark in colour, with no

yolk, and the follicle consists only of the theca.

2. The ovarian wall is very thin and may consist only of its external membrane.

3. The bands of connective tissue extending across the gonad give it an obvious lamellar structure in longitudinal section.

4. The blood vessels are small, with the exception of the central vessels passing through the gonad.

Stage II

Stage II corresponds to the beginning of the oocyte maturation phase. This involves complete development of the follicle, the beginning of vitellogenesis and the appearance of the chorion (oocyte membrane). These changes are accompanied by a substantial increase in the diameter of the maturing oocytes, from 130 µm to approximately 300 µm. Since the production of new oocytes is almost completed, the growth of the ovary is hence due primarily to the growth of the existing cells.

Follicle:

The follicle is completely formed at the beginning of stage II. It consists at this point of two layers: the theca on the outside and the granulosa layer on the inside. The formation of the granulosa marks the beginning of the oocyte maturation phase. In the initial stages of its formation, the granulosa is more difficult to distinguish; its cells are flattened, pressed against the theca and separated from one another (Figure 6). However, the granulosa cells increase rapidly in number and size during stage II, forming a distinct and readily observable layer.

As the granulosa develops, the cytoplasm of the oocytes loses its affinity for hematoxylin staining (blue, Bowers and Holliday, 1961). The cytoplasm of those oocytes with a granulosa layer appears lighter at this stage than that of the other oocytes. When the granulosa is difficult to distinguish, this characteristic can be used for indirect identification of those oocytes which have begun their maturation phase (Figure 7).

Vitellogenesis:

Vitellogenesis begins shortly after formation of the granulosa. The yolk is not a clearly defined chemical substance; it may consist of proteins, phospholipids, neutral fats and glycogen (Le Moigne, 1979). However, two principal types of yolk inclusions have been identified in the Atlantic herring (Bowers and Holliday, 1961; Polder, 1961) and in the Pacific herring (*Clupea pallasii*; Yamamoto, 1956); yolk vesicles and yolk globules. According to Khoo (1979), these are the only two types of yolk inclusions found in most teleosts; the yolk vesicles consist primarily of mucopolysaccharides, while the yolk globules consist primarily of phospholipids.

According to our observations, the two types of yolk inclusions described by Polder (1961) and Bowers and Holliday (1961) are present in stage II. Like these authors, we find that the vesicles are produced before the globules; they take the form of large white or purplishblue vacuoles (Figures 6, 7 and 8). The white vacuoles probably represent a poor reaction by the yolk vesicles to hematoxylin-eosin staining. According to Khoo (1979), the vesicles react more satisfactorily to Mallory's trichrome.

The yolk vesicles are observable first around the periphery of the oocyte cytoplasm (Figures 6 and 7), then extend towards the centre of the cell (Figure 8). As the oocytes develop, the vesicles grow in size and number. The production of yolk vesicles begins in oocytes approximately 150 µm in diameter.

Towards the end of stage II, production of the second type of yolk

begins. This occurs in the form of small droplets, or globules, more intensely stained by eosin (pink) than the yolk vesicles. However, the yolk vesicles are present still only in small numbers throughout stage II and only around the periphery of the cell (Figure 9).

Chorion:

The chorion represents the egg membrane. In its complete form, it consists of three layers: a very thick outer layer, with a roughly striated appearance, and two finely striated inner layers, thinner than the outer layer (Figure 15; Bowers and Holliday, 1961). Polder (1961) considers the two inner layers a single layer.

According to Bowers and Holliday (1961), the outer layer is the first to become differentiated. Our observations indicate that it is the centre layer which develops first, towards the middle of stage II (Figure 9). The outer layer, which is identifiable by its more roughly striated appearance, does not appear until the very end of stage II. Unfortunately, the histological sections available do not allow us to establish this fact with certainty. The striations, which correspond to pores (Polder, 1961), are more difficult to detect when the outer layer is just beginning to form. This would explain the difficulty in distinguishing the outer layer from the centre layer in the initial stages of their formation. Only these two layers of the chorion can be observed in stage II.

Resting and maturing oocytes:

The maturation phase described above does not occur for all oocytes present in the gonad in stage I. Only a portion of the gonad's oocyte reserve will undergo maturation within the current year; the other oocytes will remain in a resting state until the spawning season of the following year (Naumov, 1956). It thus becomes progressively easier, as stage II advances, to divide the cells present into two groups: the maturing cells (light coloured, with the granulosa and yolk) and the resting cells (dark coloured, with no yolk and the theca as the only follicular layer, Figures 7 and 8).

When their development ceases, the resting cells may have a diameter equal to that of the oocytes at the end of stage I (approximately 130 µm). They remain at this stage until a new maturation cycle begins.

Identification criteria used:

Stage II can be divided into two parts, stages IIa and IIb. The criteria used to distinguish these two parts are as follows:

STAGE IIa (Figures 7 and 8)

1. Distinguished from stage I by the appearance of oocytes with lighter coloured cytoplasm.

2. Later, production of yolk vesicles begins, but not that of yolk globules.

The appearance of oocytes with lighter coloured cytoplasm is also used by Bowers and Holliday (1961) to separate stages I and II. In contrast, Polder (1961) makes this distinction at the point at which the production of yolk vesicles begins in the oocytes. According to our observations, the Bowers-Holliday criterion corresponds more closely to the transition from stage I to stage II as defined by the CAFSAC key.

STAGE IIb (Figure 9)

Appearance of the first yolk globules, which are still present only in small numbers and occupy only a very narrow band of cytoplasm around the periphery of the oocyte.

The formation of the granulosa and of the first two layers of the chorion are considered more difficult to observe and

have not been used as priority identification criteria for the separation of stages I, IIa and IIb. However, observation of these structures remains useful in assessing the precise level of gonad maturation in stage II.

Stage III

Stage III involves extensive production of yolk globules, and the completion of chorion formation. Formation of the yolk globules remains the predominant characteristic of this stage. These globules are found throughout the cytoplasm of the oocyte by the end of stage II. This vitellogenesis contributes to the growth in oocyte diameter, which may increase from 300 µm to approximately 500 µm over the course of this stage.

Production of the yolk:

As the production of yolk globules proceeds, the band which they form around the periphery of the oocyte becomes larger (Figure 10). By the end of stage III, the yolk globules occupy the entire cytoplasm of the oocytes (Figures 11 and 12). At this point, the yolk vesicles are generally grouped together around the periphery of the cell (Figure 12).

Chorion:

The centre and outer layers of the chorion gradually become thicker throughout stage III. The striations of the outer layer then become more readily visible (Figure 13). The thickening of the first two layers of the chorion coincides with the appearance of the inner layer. However, even at the end of stage III, this inner layer remains very thin and difficult to distinguish.

Identification criteria used:

Stage III can also be divided into two parts (IIIa and IIIb), on the basis of the following criteria:

STAGE IIIa (Figure 10)

1. The yolk globules occupy up to half the cytoplasm of the oocytes, in the area around the periphery.

2. In most of the oocytes, the portion (half) of the cytoplasm adjacent to the nucleus contains no yolk globules.

STAGE IIIb

1. The globules occupy the entire cytoplasm of the oocytes (Figure 11), but the nuclei of most of the cells are clear of yolk globules.

2. The vesicles can be observed throughout the cytoplasm of the oocytes (Figure 11), but by the end of stage III, they are generally beginning to group around the periphery of each cell (Figure 12).

The criteria selected to distinguish stages II and III correspond generally to those used by Polder (1961) and apply well to the macroscopic definition used by CAFSAC for these two stages.

The changes which occur in the layers of the chorion are too difficult to assess to constitute an objective criterion for classification.

Stage IV

In stage IV, the diameter of the oocytes may increase to as much as 650 µm. The yolk globules are pressed against the nuclear membranes of most of the oocytes (Figure 14). In some cases, the globules may even penetrate this membrane (Polder, 1961), giving the nucleus an irregular appearance. As stage IV progresses, the yolk vesicles become less visible, while the yolk globules increase in volume by fusing with one another (Polder, 1961). However, according to our observations, this fusion appears to remain limited in stage IV.

The follicle and the chorion undergo certain changes associated with the increase in oocyte diameter. First, the theca becomes larger and the granulosa cells increase in number (Bowers and Holliday, 1961) and, secondly, the chorion becomes thicker and its inner layer more readily observable by the end of stage IV (Figure 15).

Identification criteria used:

1. The yolk globules are pressed against the nuclear membrane (Figure 14) and may even infiltrate the nucleus.

2. The yolk vesicles generally form only a narrow band around the periphery of the oocytes (Figure 14).

The gradual return of the yolk vesicles to the periphery of the oocytes provides additional information for the determination of this stage, but the distribution of the yolk globules in the oocyte is used as the primary criterion for classification. This criterion allows the establishment of a closer correspondence with stage IV of the CAFSAC key.

Polder (1961) and Bowers and Holliday (1961) also consider that the period corresponding to stages III and IV is related primarily to a continuous process of yolk production. However, they offer few details on the criteria used to separate these stages.

Stage V

In stage V, the oocytes may reach as much as 750 µm in diameter. The nucleus begins to become decentralized (Figure 16). This migration of the nucleus towards one of the poles of the cells has been observed by a number of authors, including Polder (1961), Gokhale (1957) in *Gadus merlangus* L, and Wallace and Selman (1977) in *Fundulus heteroclitus*.

By the very end of stage V, the fusion of the yolk globules is clearly visible, giving the oocytes a very different appearance (Figure 17). At this point, the nucleus may be elongated and pressed against the wall of the oocyte, or it may no longer be apparent.

Identification criteria used:

1. Distinguished from stage IV by the beginning of the decentralization of the oocyte nuclei (Figure 16)

2. The oocytes are still surrounded by their follicles (Figures 16 and 17).

Stage VI

Stage VI corresponds to the mature gonad, ready for spawning. Ovulation marks the passage of the ovary into stage VI. It occurs once fusion of the yolk globules has become clear and the nucleus is no longer apparent. Ovulation involves the expulsion of the eggs from their follicles. The ovulated eggs then accumulate in the central portion of the ovary, displacing the empty follicles and resting oocytes towards the periphery of the gonad (Figure 18). Shortly after ovulation, spawning occurs and most of the eggs are expelled from the ovary.

The ovulated eggs may be over 1 mm in diameter. This sudden increase in the diameter of the oocytes from stage V to stage VI is related to their release from the follicles, leading to their rapid swelling through the absorption of water (Polder, 1961).

The ovarian wall, previously stretched thin by the expansion of the gonad, begins to become thickened and contorted as the eggs are expelled from the ovary. At this point, it contains a large number of prominent blood vessels, dilated during the maturation process.

Identification criteria used:

1. Distinguished from stage V by the absence of follicles around the

oocytes (ovulation completed - Figure 18).

2. Large numbers of mature eggs are still present in the central portion of the ovary.

The absence of follicles around the oocytes is also used by Polder (1961) to distinguish stages V and VI. However, Bowers and Holliday (1961) feel that ovulation has not yet occurred at the beginning of stage VI. Polder's criterion has been selected, since it permits ready distinction between these two stages and relates the microscopic definition of stage VI to the macroscopic definition offered for the same stage in the CAFSAC key.

Stage VII

Stage VII corresponds to the period immediately following spawning. At this stage, the gonad contains only resting oocytes, the remnants of follicles and, occasionally, a few mature eggs not expelled from the ovary during spawning (Figures 19 to 22).

The remnants of follicles and non-resorbed mature eggs provide clear evidence of previous spawning. However, indications that previous spawning has occurred (spawning marks) can also be provided by observation of the vascular system and of the infrastructure of the ovary. The vascular system is still well developed after spawning (numerous prominent blood vessels) and hematomas may be observed in the gonad (Figure 20). Finally, the ovarian wall and the bands of connective tissue extending across the ovary are generally thick and contorted (Figure 20) and the lamellar structure of the ovary is no longer evident (Figure 21).

The spawning marks are not necessarily all present in the same specimen. Evidence that an individual has already spawned may be provided by only one of these indications. However, the spawning marks are usually numerous and evident in stage VII, since this stage merely marks the beginning of the period of gonad reconstruction. This period implies the initiation of two major processes: resorption of the spawning marks and production of a new line of oocytes.

Resorption of spawning marks

Little resorption of spawning marks occurs during stage VII. In general, the principal changes observed are a reduction in the contortions of the ovarian wall and the bands of connective tissue, together with gradual reconstruction of the lamellae of connective tissue which support the oocytes as they are produced (Figure 22). These changes make the gonad smaller and firmer. The other spawning marks show little change through stage VII; the empty follicles and mature eggs are not yet resorbed and hematomas are still apparent.

Production of a new line of oocytes:

The stages in the production of a new line of oocytes are the same as those described in stage I. The newly produced oocytes are approximately 15 µm in diameter and are readily distinguished from those of approximately 130 µm already present at the beginning of stage VII. They are found in the redeveloping connective tissue lamallae (Figure 22).

Identification criteria used:

1. Distinguished from stage VI by the fact that almost all of the eggs have been expelled from the gonad. The few mature eggs still present are considered to be undergoing resorption.

2. The young oocytes present in the ovarya re similar to those described in stage I. They have not yet begun the maturation phase; they are dark in colour, with no yolk, and the theca is the only follicular layer.

3. Distinguished from stage I by the presence of one or more of the following spawning marks (Figures 19 to 22):

   a) presence of empty follicles;
   b) presence of a few mature eggs (ovulated or unovulated), not expelled from the ovary during spawning;
   c) thickening and contortions of the ovarian wall and of the bands of connective tissue;
   d) lamellae of connective tissue absent from the gonad or, at least, from its central portion;
   e) presence of hematomas;
   f) presence of prominent blood vessels.

Stage VIII

Stage VIII represents the final step in the gonad reconstruction phase and the beginning of a new maturation cycle. At this point, we observe the final resorption of the spawning marks, completion of the production of new germ cells and the beginning of a new phase of oocyte maturation. The third point is the primary characteristic of stage VIII.

Oocyte maturation phase:

According to Naumov (1956), the oocyte maturation phase involves only those oocytes already present in the gonad at the beginning of stage VII, the development of which was interrupted the preceding year. As far as we are concerned, it seems plausible that the oocytes produced the preceeding year are among those maturing a year later, since they do not deteriorate when development ceases. However, we have no evidence that oocytes produced in stage VII of a given year do not complete their maturation the same year.

The oocyte maturation which occurs in stage VIII involves the same steps described in stage II: the cytoplasm of the oocytes becoming lighter in colour (Figures 23 to 26), the production of the two types of yolk (Figures 27 to 30) and the formation of the follicle and of the first two layers of the chorion. As at the end of stage II, late stage VIII oocytes have few yolk globules, all of which are found around the periphery of the cell. The only difference between stages VIII and II involves the spawning marks, present in stage VIII. The oocytes then go on to stage III and the maturation cycle begins again.

Final resorption of spawning mark

Spawning marks are generally evident until the end of stage VIII. However, they are more apparent in some individuals than in others. Some late stage VIII specimens (Figures 29 and 30) may show more obvious spawning marks than others at the beginning of the same stage (Figure 24). This difference may be attributed to substantial differences in the visibility of the spawning marks as early as stage VII, or to differences in the energy available to each individual after spawning to initiate a new maturation cycle and, at the same time, resorb the residues from the previous spawning cycle.

The connective tissue lamallae present in the ovary are generally reconstructed early in stage VIII, but spaces frequently remain between the lamellae, particularly in the central portion of the ovary (Figures 24 and 25). This phenomenon may be related, in part, to the poor condition of some histological sections, since it can be observed, to a less pronounced extent, in some stage II specimens (Figure 7). However, spacing between the lamellae has been observed much more frequently in specimens showing clear spawning marks, suggesting that it is probably due as well to incomplete reconstruction following spawning.

Empty follicles are rarely visible once vitellogenesis begins. Mature eggs resist resorption longer and may be present until the end of stage VIII. Their slower resorption may be related to their large size and to the chorion, which

is believed to be more resistant to resorption (Polder, 1961).

Ovaries containing mature eggs in resorption can be readily associated with an individual which has previously spawned. Unfortunately, few histological sections show such eggs. For most late stage VIII individuals, previous spawning must be detected on the basis of less obvious, but generally longer lasting, spawning marks. These include thickening and contortions of the ovarian wall and of the bands of connective tissue (Figures 26, 28 and 30), the presence of prominent blood vessels (Figure 27), or the presence of hematomas in the ovary (Figures 28, 29 and 30).

Identification criteria used:

Stage VIII can be divided into three parts (VIIIa, VIIIb and VIIIc) on the basis of the following criteria:

STAGE VIIIa (Figures 23 to 26)

1. Distinguished from stage VII by the appearance of oocytes with lighter coloured cytoplasm, that is, oocytes at the beginning of the maturation phase.

2. Yolk production has not yet begun.

3. Distinguished from stage II on the basis of the same spawning marks as in stage VII, except that the lamellar structure of the ovary has generally been reconstructed. Open spaces may, however, subsist between the connective tissue lamallae.

STAGE VIIIb (Figures 27 and 28)

1 .Presence of yolk vesicles, but no yolk globules.

2. Distinguished from stage II by the same spawning marks as in stage VIIIa, except that the empty follicles have generally been completely resorbed.

STAGE VIIIc (Figures 29 and 30)

1. Appearance of the first yolk globules, although they are still present only in small numbers and occupy only a very narrow band of cytoplasm around the periphery of the oocytes.

2. Distinguished from stage II by the same spawning marks as in stage VIIIb, although these are generally less evident.

The margin of error in the distinction of stages II and VIII grows as spawning marks become less evident. The risk of error becomes greater when this distinction is based solely on the presence of hematomas in the ovary, or of spaces between the lamellae of connective tissue, since these characteristics can be affected by the condition of the sampled specimen and by the condition of the histological section.

The period of gonad reconstruction (stages VII and VIII) is described only very briefly by Polder (1961) and Bowers and Holliday (1961). These authors feel that it becomes impossible to distinguish an individual which has already spawned once vitellogenesis has begun (beginning of stage VIIIb). Our observations clearly establish that the it remains possible to distinguish between a virgin herring and a repeat spawner, in most cases, until the point at which the production of yolk globules begins (stage VIIIc).

MACROSCOPIC CLASSIFICATION

Stage I

At the beginning of stage I, the gonad is approximately 1 mm wide and occupies up to one third of the length of the body cavity. It is flattened and rather whitish (almost transparent). Sex cannot be determined with the naked eye. This description corresponds generally to herrings under 200 mm in length, in which production of the line of germ cells

(oocytes) in the ovary is not complete (Figure 2).

Towards the end of stage I, the gonad may be as much as 3 mm wide and up to half the length of the body cavity. The eggs are not visible to the naked eye. The cylindrical shape of the gonad, with its pointed anterior end and orangey red colour, typical of females, make it easy to determine the sex at this stage. This description would apply to herrings between 200 and 300 mm in length and about to begin their first maturation cycle. Their gonads contain a large number of oocytes (Figure 3), but the principal maturation phase, associated with vitellogenesis, has not yet begun.

The passage of the gonads from a flattened to a cylindrical shape during stage I is probably due to the increase in the number of oocytes. The orangey red colour may be related, in part, to the development of the vascular system, which occurs as the number of oocytes increases.

Stage II

The ovaries occupy between half and 2/3 of the length of the body cavity and vary in width between 3 and 8 mm (Figures 31 and 32). The width may be the same for the entire length of the gonad, or narrower at the posterior end (3 to 5 mm) and widest in the central portion (5 to 8 mm). The colour may be red, orange, or even light yellow. The eggs are transparent and still difficult to see with the naked eye (Figure 33).

Gonad colour should not be considered a reliable criterion for identification, even with fresh samples. The use of gonad width and length in relation to that of the body cavity is recommended for distinguishing between stages I and II.

This stage cannot be divided into two parts, as at the histological level, on the basis of macroscopic criteria, since this would involve too wide a margin of error.

Stage III

The ovary occupies between 2/3 and the total length of the body cavity. It varies in width between 5 and 10 mm at the posterior end and between 10 and 20 mm at its widest point. Its colour is generally a mixture of golden yellow and orange (Figure 34), but may also be wine red (Figure 35, which corresponds to Figure 11), or brownish, when hematomas are present in the ovary.

The eggs are transparent at the beginning of stage III, but become increasingly opaque as this stage progresses. This change coincides with the progressive infiltration of the oocytes by the yolk globules. From the beginning of stage III, the eggs are readily visible to the naked eye (Figure 36). This criterion is more objective than the colour and dimensions of the gonad and has been given priority in distinguishing stages II and III.

The microscopic distinction established between the beginning and end of stage III (IIIa and IIIb) has no clear macroscopic counterpart. The gonads obviously tend to increase in length and width during this stage, while the orange tints become less marked (Figure 37) and the eggs become increasingly opaque. However, none of these criteria can be reliably used in the field to divide stage III into two parts.

Stage IV

The ovary is generally the same length as the body cavity. It is over 10 mm wide at the posterior end and may be over 20 mm wide at its widest point. The colouring may include some orange tints, but in most cases it varies from light yellow to almost whitish (Figure 38). The eggs are opaque and larger in diameter than in stage III.

Although very imprecise, assessment of ovary width constitutes the best criterion for distinguishing stages III and IV. The colouring of the ovary and

its length may provide additional information, but must not be considered priority criteria for the identification of this stage.

Stage V

The ovaries occupy the entire volume of the body cavity, compressing the digestive tract and the other organs. The ovaries are 10 mm wide at the posterior end and up to 30 mm wide at the widest point. At the beginning of stage V, the gonad is generally whitish, or light yellow, as in stage IV. By the end of stage V, the colour of the ovary may be lighter (light yellow; Figure 39) or may include some very characteristic brownish tints (Figure 40). The latter appear to coincide with the period of marked fusion of the yolk globules, which precedes ovulation.

A few transparent eggs may occasionally be observed in the ovary in stage V. Ovulation and subsequent absorption of water by the oocytes are responsible for the transparency of the mature eggs (Polder, 1961). The few transparent eggs visible in stage V may thus have passed through these steps more rapidly, since ovulation does not occur, for the majority of the oocytes, until the transition between stages V and VI.

The volume which the gonads occupy in the body cavity and the presence of a number of transparent eggs should be considered the most reliable characteristics for distinguishing stages IV and V.

Stage VI

The ovary is striated and red on the dorsal half and light yellow on the ventral half. It is generally flaccid and separates into lamellae. The eggs are transparent, much larger in diameter than in stage V (because of water absorption following ovulation; Polder, 1961) and may flow freely.

The light yellow colour of the ovary appears to be accentuated by the transparency of the eggs. The striated appearance of the gonad is caused by the more pronounced vascularization of the ovarian wall (Bowers and Holliday, 1961).

Egg transparency (all eggs transparent) constitutes the best criterion for separating stages V and VI. The separation of the lamellae gives additional information, but this characteristic may be accentuated when the ovaries are in poor condition. The substantial increase in the diameter of the eggs can also be used, but its assessment, even on the basis of precise measurements, would be open to error since it would not take into account individual variations in egg diameter at maturity (Baxter, 1959).

Stage VII

A stage VII ovary is one from which most of the eggs have been released. Immediately after spawning, the gonad may be the same length as the body cavity and over 20 mm in width. It is extremely flaccid, bloodshot (wine red in colour-Figure 41) and may contain a substantial quantity of material to be resorbed, or be completely empty.

Once resorption has begun (end of stage VII), the gonad occupies approximately 2/3 the length of the body cavity (Figure 42) and may be reduced to 5 mm in width. It is firmer at this point (only when little residue remains from the previous spawning) and may be light yellow or orange in colour at one end (usually the anterior end). This increased firmness is probably related to the extensive thickening of the connective tissue.

Stage VIII

At the beginning of stage VIII (microscopic VIIIa), the ovary occupies approximately 2/3 the length of the body cavity and varies in width between 3 and

8 mm. It is completely wine red, or orangey yellow at the anterior end and wine red at the posterior end (Figure 43). It contains a large number of eggs, difficult to see with the naked eye, which give it a cylindrical shape (Figure 44) and greater firmness than in stage VII, when little spawning residue is present in the ovary. Otherwise, the ovary remains flaccid, despite the fact that the number of eggs has increased.

The histological distinction established between stages VII and VIII corresponds primarily to an increase in the number of maturing oocytes in the gonad. The cylindrical shape of the ovary thus constitutes the best criterion for detecting this change (Figures 42, 43 and 44). The firmness of the gonad can also be used, but this parameter is less reliable than the preceding one, since it can be distorted by the variable quantity of residue left in the gonad.

In the case of fresh samples, the distinction between stage II and the beginning of stage VIII can be established on the basis of the wine red colour and striations of the gonad (related respectively to the presence of hematomas and prominent blood vessels), which are generally more evident in stage VIII. However, the use of this criterion may involve certain errors, since wine red tints may also be observed in certain specimens in stage II, particularly frozen specimens. In these instances, the relative length of the gonad may be used. The stage VIII gonad may be longer (over 2/3 the length of the body cavity, rather than 1/2 to 2/3) because of incomplete contraction (Figures 31, 32 and 43). However, this parameter may be quite variable.

As stage VIII progresses, the elongated appearance and wine red colour of the ovary become less marked. At this point, it may be between one half and over 2/3 the length of the body cavity and between 5 and 10 mm wide. The colour is orangey red or orangey yellow (Figure 45). The eggs are more numerous and larger, but are still difficult to see with the naked eye. Late stage VIII is thus very difficult to distinguish from stage II. Only the width of the gonad which, in general appears slightly greater in stage VIII (5-10 mm vs 3-8 mm) can be used. However, distinguishing between stages VIII and II on the basis of this information can involve a wide margin of error.

The ovary then passes into stage III. Passage of the ovary from stage VIII into stage III is determined in the same way as from stage II to stage III, that is, on the basis of the visibility of the eggs to the naked eye (Figures 36 and 44).

DISCUSSION

Histological classification

Most of the microscopic descriptions associated with each of the eight maturity stages of the CAFSAC classification correspond to those provided by Bowers and Holliday (1961) or by Polder (1961). However, the criteria selected (Appendix 2) to distinguish each maturity stage have been more clearly defined. The gonad reconstruction period has also been more thoroughly documented; virgin herrings and repeat spawners can generally be distinguished until the point at which the first yolk globules are produced (stage VIIIc), and not merely until the beginning of stage VIIIb, as these authors believe.

Certain parts of the reproductive cycle are more difficult to divide into maturity stages. This is true primarily of the period corresponding to stages III to V, classification of which must be based on a rough assessment of the development of yolk globules in the oocytes (Appendix 2). The criteria selected to classify these stages make it possible, however, to define in detail the principal phase of gonad growth prior to spawning. In addition, these criteria are compatible with the stages defined in the CAFSAC key.

The concern for compatibility with CAFSAC may account for some further imprecision in the microscopic identification of certain maturity stages. For example, the separation of stages II (or VIII) and III must be based on an estimate of the size of the band of yolk globules present around the periphery of the oocytes. This separation might have been defined simply by the production of the first yolk globules. However, this change would make the visibility of the eggs to the naked eye a less appropriate criterion for distinguishing stages II (or VIII) and III. In addition, this change would require the classification to stage III of certain individuals in which the spawning marks are still evident, thus making it more difficult to maintain the distinction between a virgin herring and one which has previously spawned.

The histological study has enabled us to divide the female reproductive cycle into twelve stages, rather than eight. The further subdivisions added to stages III (IIIa and IIIb) and VIII (VIIIa, VIIIb and VIIIc) make it possible to detail one of the periods in which separation of the spawning groups on the basis of maturity stage is recognized as the least certain, because of the risk of overlapping between the two stocks at certain periods of the year (Cleary et al. 1982). Our observations confirm this hypothesis for stage VIII; individuals spawning in mid-May can remain in stage VIII for a good part of the summer, while autumn spawners appear to pass from stage VIII to complete maturity between June and September. Herrings collected in June and classified as early and late stage VIII may thus belong to different spawning groups and only subdivision of stage VIII can permit their distinction. Moreover, the gonadosomatic index associated with the subdivisions of stage VIII has enabled McQuinn (1989) to separate the two spawning groups during the month of June. The subdivision of stage III into two parts (IIIa and IIIb) has also been used by McQuinn (1989), who believes that the two spawning groups may overlap in April and May, for individuals in stage III.

The maturity stage is not generally used to differentiate the spawning groups in the case of virgin specimens (stages I and II); this distinction is based on otolith characteristics (Cleary et al. 1982). However, the subdivision of stage II into two parts (IIa and IIb, corresponding respectively to stages VIIIa and VIIIb-VIIIc) has been maintained. It may be relevant in establishing whether the beginning of the oocyte maturation phase (lighter coloured oocytes and production of the first yolk vesicles) does in fact imply the beginning of an initial maturation cycle, leading to integration of the juveniles with the spawning individuals.

Macroscopic classification

The problems associated with the CAFSAC classification are not related solely to lack of information on gonad changes from one stage to another, but also to a lack of detailed information on the priority to be assigned to the various criteria available to separate the transition stages. This problem contributes to the variety of interpretations reached by users of the CAFSAC key. The principal improvements suggested for this key thus do not relate primarily to the addition of new criteria, but to the definition of the priority criteria to be used to distinguish between each maturity stage. This order of priority (Appendix 3) should be incorporated into the CAFSAC key.

In general, gonad colour does not represent a reliable characteristic for the determination of maturity stage, even with fresh samples.

The separation of stages I and II and that of stages III and IV should be based primarily on assessments of gonad width. The relative length of the gonads can offer additional information, but it should be considered a secondary criterion. Relative gonad length is listed only for stage IV in the CAFSAC key. This information should therefore be added for the other stages.

The gonad width values listed for each maturity stage relate to general cases and do not take into consideration the fact that this parameter may vary considerably (within a given stock) with the size of the fish. The relationship between gonad width and fish size (for each maturity stage) has not been precisely determined in this study. In any event, this relationship would probably only partially eliminate the overlap in gonad width values between the various maturity stages. The use of this parameter for the separation of stages I and II and of stages III and IV thus involves a certain margin of error.

It is noted in the CAFSAC key that the gonads may occupy approximately half of the central cavity (we assume that this refers to gonad volume) and that they may be between 1 and 2 cm wide. According to our observations, it seems that the volume of gonads 1 to 2 cm wide may be considerably greater than one half that of the body cavity (Figure 37). This point clearly indicates the principal problems associated with the CAFSAC classification. First of all, the values given for gonad volume do not represent all the possibilities for stage III. Secondly, there is no clear indication which of the criteria, gonad width or volume, should be given precedence when the values for one of the two criteria do not correspond to those given in the key. We have noted gonad volume only for stage V (100% of the volume of the body cavity). This parameter might have been used as a supplementary criterion to gonad width and relative length in classifying certain other maturity stages. However, approximate estimations of gonad volume would also involve a wide margin of error, while precise assessments would be too time-consuming for the limited additional information they could offer.

Stages II (or VIII) and III can be distinguished relatively precisely by the visibility of the eggs to the naked eye. The importance of egg characteristics in separating stages II to V is emphasized in the CAFSAC key, but it is not clearly indicated that stages II (or VIII) and III must first be separated on the basis of this criterion. Were this the case, the need for better documentation of stage VIII (on the basis of the histological method) would be less pressing, at least for females.

The ovaries should be considered in stage V when their volume is equivalent to that of the fish's body cavity. This criterion and that of the transparency of some eggs are mentioned in the CAFSAC key. However, priority should be assigned to gonad volume, since transparent eggs are observed only in some individuals and generally at the end of stage V. This criterion is thus not particularly useful for the transition period between stages IV and V. The transparency of all the eggs, however, is a reliable characteristic for distinguishing between stages V and VI. This information is already available in the CAFSAC key, but should take precedence over the freely flowing nature of the eggs, which can be affected by the state of preservation of the gonad.

The separation of stages VI and VII does not constitute a problem. The flaccid appearance of the ovaries, their wine red colour and the fact that they are generally empty, as stated in the CAFSAC key, permit ready distinction of these stages. Maturity staging becomes more difficult as the period of gonad reconstruction progresses, and the information provided in the CAFSAC classification for this period is inadequate. For example, the distinction between stages VII and VIII is not documented. This distinction is based primarily on the cylindrical shape assumed by the ovary as new oocytes are produced (in stage VIII). The stage VIII ovary may also be firmer than in stage VII, but this criterion can be affected by the variable quantity of residue remaining in the gonad.

The CAFSAC key also provides little information on the distinction between stages VIII and II, and what it does provide is occasionally erroneous. For example, the greater firmness of the ovary

in stage VIII mentioned in the CAFSAC key does not appear to be consistent with the facts. In fact, it is the stage II ovary which may be firmer, particularly when the stage VIII gonad contains a large quantity of residue. When residue is less plentiful, gonad firmness does not permit separation of these two stages. This separation can often be based on the wine red colour and striations, which are generally more evident in stage VIII. This criterion is already included in the CAFSAC key, but should be given priority. When differences in colour are less evident (particularly with frozen samples), the relative length of the gonads can be used to separate stage VIII (the beginning only) from stage II. This is generally greater in the early part of stage VIII (over 2/3 the length of the body cavity, rather than 1/2 to 2/3), because of incomplete contraction. However, this parameter can involve substantial errors.

At the end of stage VIII, the wine red colour and relative length of the gonads no longer permit distinction from stage II. Only the width of the ovaries may be greater in stage VIII (5 to 10 mm rather than 3 to 8 mm). This possibility is mentioned in the CAFSAC key, but no values are given for gonad width. The values provided for stages VIII and II can thus be added to the CAFSAC key, although they may involve a wide margin of error. In fact, these two stages relate to identical levels of development, the only difference being that one specimen is virgin while the other has spawned previously. The distinction between stages II and VIII thus represents the principal area of difficulty in the macroscopic method of determining maturity stage in females.

EVOLUTION OF TESTICULAR MATURATION

HISTOLOGICAL CLASSIFICATION

Stage I

Stage I corresponds to the organization of the connective tissue and the vascular system in the gonad, and to the beginning of the production of germ cells. This production is responsible for the growth of the gonad.

Organization of the connective tissue:

The infrastructure of the testis consists of a wall from which ramifications of connective tissue extend through the gonad (Figure 46). The wall consists of an outer membrane, below which develops a thick fibrous layer, although it is often incomplete in stage I. The wall is generally much thicker in the dorsal portion of the gonad. The ramifications of connective tissue extending through the gonad will eventually form the walls of the seminiferous tubules. These contain the maturing germ cells.

Once established, the structure of the seminiferous tubules resembles a series of branching channels, all leading into the sperm duct, the channel through which sperm is discharged during spawning (Figure 46). At the beginning of stage I, the structure of the seminiferous tubules is not yet defined; the connective tissue is distributed in a loose network of fibres throughout the gonad (Figure 47). By the end of stage I, the connective fibres show some initial organization around the newly formed germ cells, but the structure of the seminiferous tubules remains difficult to distinguish.

Germ cells:

As in the case of the ovary, the level of development achieved by the germ cells determines the maturity stage of the testis. Two types of germ cells can be identified in a stage I testis: the primary germ cells and the spermatogonia (Figures 47 and 48). According to Bowers and Holliday (1961), the former represent the root cells from which the spermatogonia are formed.

The primary germ cells are characterized by the large nucleolus

located in the centre of the cell and by the chromatin dispersed around the periphery of the nucleus (Figure 48). These cells may be as much as 15 µm in diameter, with a nucleus of 10 µm. The spermatogonia have a diameter of approximately 8 µm and a nucleus of 6 µm. Passage of the primary germ cells into the spermatogonium phase involves a loss of cytoplasm, but the arrangement of the chromatin and of the nucleolus remains unchanged (Bowers and Holliday, 1961). This arrangement, however, is much less evident in the spermatogonia, probably because of the more compact appearance of the nucleus.

By the end of stage I, the spermatogonia outnumber the primary germ cells. At this point, the arrangement of the connective fibres in seminiferous tubules is more clearly defined. The germ cells are generally pressed against the developing tubule walls, leaving the central portion of each tubule clear.

Vascular system:

At the beginning of stage I, the vascular system of the testis is similar to that described for the ovary. It consists primarily of one vein and one artery running the full length of the gonad (Figure 46). By the end of this stage, the vascular system has branched out between the tubule walls, to supply each of the developing seminiferous tubules individually (Bowers and Holliday, 1961).

Other types of cells:

Other types of cells are present with the germ cells. These are primarily connective cells and Sertoli cells (Bowers and Holliday, 1961; Polder, 1961). The connective cells are light in colour and elongated in shape. By the end of stage I, they are found all along the walls of the tubules and around the spermatogonia, as the latter group together, leaving the central portion of the seminiferous tubules clear. The connective cells remain difficult to distinguish in stage I. The Sertoli cells too are very difficult to distinguish, because of the cytoplasmic extensions binding them closely to the maturing germ cells (Bowers and Holliday, 1961). The Sertoli cells play an important role in the maturation of the germ cells (Bowers and Holliday, 1961), providing nourishment and acting as phagocytes during the maturation period (Grier et al., 1978).

Identification criteria used:

The two identification criteria considered determinant in classifying the testis in stage I are as follows (Figures 47 and 48):

1. The only germ cells present aret he primary germ cells and the spermatogonia. By the end of stage I, the spermatogonia outnumber the primary germ cells.

2. The structure of the seminiferous tubules remains generally undefined.

Stage II

Spermatogenesis:

Stage II corresponds to the beginning of spermatogenesis. This involves the rapid multiplication of the first spermatogonia produced by the primary germ cells and their gradual passage into the phases of primary spermatocytes ("2n" chromosomes), secondary spermatocytes ("n" chromosomes), spermatids and, finally, spermatozoa (Bowers and Holliday, 1961; Polder, 1961). These phases all appear during stage II. There is thus no need to examine them all in detail in order to determine the sexual maturity stage.

The diameter of the germ cells diminishes from one phase of spermatogenesis to the next (Bowers and Holliday, 1961). The growth of the testis during this period is thus due to an increase in the number of cells, in contrast to the ovaries at the same stage,

in which expansion is related primarily to the growth of a limited number of cells.

At the beginning of stage II, the spermatogonia represent the most advanced phase of development found in the testis (Figure 49). The first stage of spermatogenesis, the spermatogonium multiplication phase, begins at this point. The spermatogonia are more numerous at this time than the primary germ cells, which are confined to small isolated groups.

As their numbers increase, the spermatogonia form distinct groups of cells around the periphery of the seminiferous tubules (Figure 50; Bowers and Holliday, 1961). Similar groupings of cells have also been reported by Turner (1919), Foley (1924) and Grier et al. (1978), in other species of teleosts. The latter three authors attribute their formation to the Sertoli cells, which, they believe, keep the germ cells grouped together and define the boundaries of each of these groups.

The primary spermatocytes are approximately 3 µm in diameter (Bowers and Holliday, 1961) and appear to be less sensitive to hematoxylin staining. Passage of the primary spermatocytes into the other phases of spermatogenesis occurs rapidly. Once in the spermatozoon phase, cell diameter does not exceed 1 µm. The spermatozoa are formed by condensation of the chromatin of the spermatids, causing expulsion of the cellular cytoplasm (Bowers and Holliday, 1961). This condensation is followed by deformation of the nucleus and the appearance of a flagellum approximately 20 µm long. The spermatozoa thus resemble tiny dark blue or black dots (Figure 51), each with a long, almost transparent, flagellum.

The spermatozoa are located in the centre of the seminiferous tubules, with the groups of less mature cells around the periphery. As the germ cells develop into spermatozoa, their arrangement in distinct groups disappears. However, the spermatozoa remain massed together, since their heads are still attached to the Sertoli cells (Grier et al. 1978).

The appearance of the first spermatozoa in the seminiferous tubules marks the end of stage II. The spermatozoa are initially observed in only a few tubules (Figure 51), since some cells within each group may develop more rapidly (Foley, 1924).

Connective tissue and vascular system:

The vascular system shows more extensive ramification than in stage I. It is possible to observe the beginning arrangement of the connective tissue in seminiferous tubules, but their formation is still incomplete (Figures 49, 50 and 51).

Identification criteria used:

Stage II can be divided into two parts (IIa and IIb), distinguished on the basis of the following criteria:

STAGE IIa (Figure 49)

1. The distinction from stage I is based on the larger proportion (arbitrarily determined) of spermatogonia in stage II. Generally, the primary germ cells are confined to small isolated groups, with the remainder of the seminiferous tubules occupied by spermatogonia.

2. Spermatogenesis begins, but the germ cells present have not yet developed beyond the spermatogonium phase.

3. The formation of the seminiferous tubules is better defined than in stage I, but is still incomplete.

STAGE IIb (Figures 50 and 51)

1. The spermatogonia pass into the primary spermatocyte phase, and on into the other stages of the spermatogenic cycle.

2. Spermatozoa appear rapidly, but they are still present only in small numbers and in only a few seminiferous tubules.

The criteria selected to separate stages I and II are the same as those defined by Polder (1961) and Bowers and Holliday (1961).

Stage III

In stage III, the production of new spermatogonia and their passage into the other phases of the spermatogenic cycle continue. The number of spermatozoa in the seminiferous tubules increases gradually. At the beginning of stage III, spermatozoa are present in small numbers, but can be observed in most of the seminiferous tubules. By the end of this stage, these cells may occupy as much as one third of the area defined by the seminiferous tubules (Figures 52 and 53).

The seminiferous tubules are larger than in stage II. Their walls, like the walls of the testis, have become thinner. The seminiferous tubules are generally well defined (Figure 52), although, in some cases, the structure remains unclear (Figure 53). This lack of clarity is probably related primarily to the histological section (crumbling and poor section orientation).

Identification criteria used:

1. All the divisions of the spermatogenicc ycle can be observed, but this stage is distinguished from stage II by the presence of spermatozoa in most of the seminiferous tubules.

2. By the end of stage III, spermatozoa occupy only one third of the area defined by the seminiferous tubules (Figures 52 and 53).

The identification criteria used to distinguish stages II and III are the same as those defined by Polder (1961). Bowers and Holliday (1961) note that the number of spermatozoa in the seminiferous tubules increases after stage III, without, however, specifying the proportion of spermatozoa (in relation to the other germ cells) for this stage.

Stage IV

The production of new spermatogonia ceases during stage IV (Bowers and Holliday, 1961). This stage thus involves a gradual elimination of the intermediate phases of the spermatogenic cycle as they pass into the spermatid and spermatozoon phase. By the end of stage IV, a narrow band of spermatocytes remains around the periphery of the seminiferous tubules, but spermatozoa (together with a few spermatids) occupy the remainder (approximately 3/5) of the area defined by the tubules (Figure 54).

The primary germ cells and the remaining spermatogonia are displaced towards the tubule walls once their development is interrupted. They will remain in a resting state until the following year, when they will serve to establish a new line of germ cells (Bowers and Holliday, 1961).

Identification criteria used:

The spermatozoa occupy between one third and 3/5 of the area defined by the seminiferous tubules (Figure 54).

The criterion selected is similar to that defined by Polder (1961). Bowers and Holliday (1961) do not define the proportion of spermatozoa used to classify stage IV.

Stage V

Stage V represents the final phase in the maturation of the germ cells. At the beginning of this stage, only a few groups of spermatocytes remain around the periphery of the seminiferous tubules. The spermatozoa are still attached at the head

to the Sertoli cells (Grier et al., 1978), thus resembling dense packets of nuclei, separated by lighter spaces in which the flagella are located (Figures 55 and 56). The latter are light pink, or white, on microphotographs taken using a mercury lamp.

Towards the end of stage V, the seminiferous tubules contain only spermatozoa. At this point, the latter become detached from the Sertoli cells and uniformly distributed through the seminiferous tubules, with the result that the flagella are difficult to observe (Figure 57). This phenomenon (spermiation) is reported by Grier et al. (1978) in several teleosts.

Identification criteria used:

Stage V is divided into two parts (Va and Vb), defined by the following criteria:

STAGE Va

1. Distinguished from stage IV by the narrow band of spermatocytes remaining around the periphery of the seminiferous tubules.

2. Later, the testis contains only spermatozoa, but these continue to resemble dense packets of nuclei (Figures 55 and 56).

STAGE Vb (Figure 57)

The spermatozoa are distributed uniformly through the seminiferous tubules.

The demarcation established between stages IV and V is the same as that used by Polder (1961), but differs from that selected by Bowers and Holliday (1961). The latter feel that no spermatocytes remain in the testis after the beginning of stage V. According to our observations, Polder's criterion is more compatible than that of Bowers and Holliday with the transition between CAFSAC stages IV and V.

Stage VI

Stage VI is the spawning stage. Passage from stage V to stage VI is characterized by a loosening of the sperm from the walls of the seminiferous tubules (Figure 58). This loosening is probably linked to the beginning of sperm emission. The tubule and testicular walls are thicker at this point and the connective cells, the primary germ cells and the spermatogonia, located in the folds of the tubule walls, are more readily visible.

During spawning, sperm is discharged by contractions of the body and muscle fibres of the testicular wall (Polder, 1961). After spawning, residual sperm may remain in a certain number of seminiferous tubules.

Identification criteria used:

A loosening of the contents of the seminiferous tubules from their walls may be observed (Figure 58). Stage VI is typically represented, however, by the absence of sperm from a number of tubules.

Stage VII

In stage VII, the seminiferous tubules contain only residue (residual sperm and other debris) from the previous spawning, the germ cells which ceased to develop during stage IV and connective cells.

The quantity of residue may vary considerably between specimens (Figures 59 and 60). When no residue is apparent, other indications of previous spawning may be observed. These include primarily thickening and contortions of the testicular and tubule walls and the presence of prominent blood vessels. These changes in the connective tissue are linked to the general contraction of the testis necessitated by the discharge of its contents. The pronounced volume of the blood vessels is linked to their dilation during the maturation process, primarily in the period immediately

preceding spawning. Hematomas may also be observed in the testis, although to a less pronounced extent than in the ovary.

As in the case of females, stage VII involves the initiation of two major processes: resorption of the spawning marks and production of new germ cells.

Resorption of spawning marks:

The spawning marks show little change over the course of stage VII. Residual sperm is only beginning to be resorbed and blood vessels, when present, remain large. The volume of the testis diminishes considerably over the course of stage VII, but this general contraction of the connective tissue may serve to emphasize the thickening and contortions of the testicular and tubule walls. The structure of the seminiferous tubules then becomes more difficult to distinguish.

Production of new germ cells:

New germs cells are produced from the cells which ceased to develop during stage IV (Bowers and Holliday 1961). At the beginning of stage VII, the germ cells emerge from the folds in the tubule walls; they are found along these walls, together with a large number of connective cells (Figure 60). The germ cells at this point are present in very small numbers and may often be difficult to identify among the connective cells and residual sperm.

By the end of stage VII, the germ cells form small groups of readily identifiable cells, although these groups are present in only some of the seminiferous tubules. At this point, they have probably begun the process of division. According to our observations, these groups consist of primary germ cells and not spermatogonia. It may be that spermatogonia from the previous cycle contribute little to the initiation of the new maturation cycle.

Identification criteria used:

1. Distinguished from stage VI by the fact that most of the seminiferous tubules are empty of their sperm content.

2. The primary germ cells form small groups, but these groups are not extensive and are present in only some of the seminiferous tubules.

3. Distinguished from stage I by one or more of the following spawning marks (Figures 59 and 60):

   a) the presence of residual sperm;
   b) the thickening and contortions of the testicular and tubule walls;
   c) the structure of the seminiferous tubules, which is largely, if not entirely, undefined;
   d) the presence of prominent blood vessels;
   e) occasionally, the presence of hematomas.

Stage VIII

At the beginning of stage VIII, groups of dividing primary germ cells are apparent in the majority of the seminiferous tubules (Figure 61). P roduction of the first spermatogonia begins subsequently, followed by their phase of rapid multiplication, which constitutes the first stage of a new spermatogenic cycle. Stage VIII is thus characterized by the initiation of a new maturation cycle, in addition to final resorption of spawning marks.

Spermatogenesis:

The steps of spermatogenesis are the same as those described in stage II, that is, the phase of rapid multiplication of the spermatogonia (Figure 62 and 63) and their gradual passage into the primary and secondary spermatocyte, spermatid and finally spermatozoon phases (Figures 64 and 65). By the end of stage VIII, all phases of germ cell maturation are present

in the testis, although spermatozoa are present only in small numbers and in only a few seminiferous tubules. The testis then passes into stage III.

Final resorption of spawning marks:

As in the case of the ovary, the distinction between a virgin herring and one which has previously spawned is not always clear. Spawning marks in the testis may disappear by the beginning of stage VIII in certain individuals, while in others they are still evident at the end of this stage. It is even possible, in some stage III specimens (Figure 53), that the difficulty in distinguishing the structure of the seminiferous tubules and the presence of prominent blood vessels may be related to the incomplete reconstruction of the testis, following earlier spawning.

The residue (residual sperm, cell debris, etc) contained in the seminiferous tubules in the process of reconstruction represent the first spawning mark to disappear. Their resorption is generally completed before the end of the spermatogonium multiplication phase (Figures 61 and 62). Occasionally, residue persists longer; in this case, they are found in the central portion of the seminiferous tubules, surrounded by a wide band of spermatogonia (Figure 63).

Vascularization (prominent blood vessels and hematomas) can occasionally provide evidence of previous spawning up to the end of stage VIII. However, the characteristics of the connective tissue (thick, contorted walls) represent the most obvious, and generally the most persistent, spawning mark in stage VIII (Figures 64 and 65).

Identification criteria used:

Stage VIII can be divided into two parts (stages VIIIa and VIIIb), distinguished on the basis of the following criteria:

STAGE VIIIa (Figures 61, 62 and 63)

1. The primary germ cells form identifiable groups in most of the seminiferous tubules.

2. Spermatogonia represent the most advanced phase of spermatogenesis present.

3. Distinction from stage II is based on the same spawning marks as in stage VII, except that contraction of the connective tissue may be more marked. As a result, the structure of the seminiferous tubules may be even less clearly defined than in stage VII.

STAGE VIIIb (Figures 64 and 65)

1. Appearance of the primary spermatocytes, followed by the other stages of the spermatogenic cycle.

2. At the end of stage VIII, spermatozoa are present in small numbers and may be found in only some of the seminiferous tubules.

3. Distinction from stage II is based on the same spawning marks as in stage VIIIa, except that the residue is generally completely resorbed and contraction of the tubule walls is less evident.

As mentioned in the case of the ovaries, the period of gonad reconstruction (stages VII and VIII) is described only briefly by Polder (1961) and Bowers and Holliday (1961). Polder believes that it is impossible to recognize an individual which has already spawned once spermatogenesis has begun (end of stage VIIIa). Bowers and Holliday permit distinction between stages VIII and II until the development of the secondary spermatocytes. According to our observations, this distinction seems to be generally evident until the appearance of spermatozoa in the seminiferous tubules (stage VIIIb; Figure 65) and may even remain possible until stage III, in certain individuals (Figure 53).

MACROSCOPIC CLASSIFICATION

Stage I

At the beginning of stage I, the testis is approximately 1 mm wide and up to one third the length of the body cavity. It is flattened and rather whitish (almost transparent). Sex cannot be determined with the naked eye. This description corresponds to testes in the primary germ cell and rudimentary vascularization phase.

Towards the end of stage I, the testis may be up to 3 mm wide and as much as one half the length of the body cavity. Its brownish colour (as opposed to the orangey red of the ovary), flat (rather than cylindrical) shape and rounded (rather than pointed) anterior end make it readily distinguishable from the ovary (Figure 66).

Polder (1961) attributes the brownish colour of the testis to a mixture of the wine red (almost black) colour of the blood vessels and the rather whitish colour of the spermatogonia. The description of the late stage I testis thus appears to correspond to testes in which the production of spermatogonia is relatively advanced and the vascular system is well developed.

Stage II

The testes are 3 to 8 mm wide. Their length may occasionally be less than half that of the body cavity (Figure 67), but is generally between half and two thirds that of the cavity. The colour may be reddish grey, brownish or even beige. Colour thus cannot be considered a reliable characteristic for distinguishing between stages I and II. This distinction must be based on the dimensions (width and relative length) of the gonads.

No macroscopic correspondence can be established between the divisions of stage II (IIa and IIb) established at the histological level.

Stage III

The length of the gonad may be between 2/3 and all of the body cavity. It is 5 to 10 mm wide at the posterior end and 10 to 20 mm at the widest point. The colour may vary from pinkish grey to wine red (Figures 68, 69 and 70). The dimensions of the testis should be considered the priority criterion for distinguishing between stages II and III.

Stage IV

The testes are generally as long as the body cavity. They are over 10 mm wide at the posterior end and may exceed 20 mm at the widest point (Figures 71 and 72). The colouring may include whitish tints, linked to the increasing proportion of spermatozoa in the gonad. However, the colour of the stage IV testis may also be reddish grey or wine red. The sperm duct may be swollen in some individuals, but this swelling is generally minor and evident only in a portion of the sperm duct.

The dimensions of the gonad represent the most reliable criterion for the distinction of stages III and IV.

Stage V

The testes occupy the entire volume of the body cavity. They may be over 30 mm wide in some individuals. They are generally white in colour, with a few wine red patches, but may occasionally be pinkish grey. The sperm duct is generally swollen for its entire length and sperm can be extruded by the application of pressure (Figure 73). The swelling of the sperm duct and examination of the volume of the body cavity occupied by the gonads represent the most reliable criteria for distinguishing stages IV and V.

No macroscopic correspondence can be established with the divisions of stage V (Va and Vb) identified at the histological level.

Stage VI

The testis is more flaccid in stage VI than in stage V. Sperm flows freely, giving the gonad a viscous appearance. The sperm duct is extremely dilated.

Sperm flow may be greater in the case of samples in poor condition (crushed or less fresh gonads). It may also appear less pronounced in the case of frozen samples (Cleary et al., 1982). The dilation of the sperm duct thus constitutes a better criterion for the distinction of stages V and VI.

Stage VII

Testes are classified in stage VII when they are empty of the greater proportion of their contents. At the beginning of stage VII, the testes may be as long as the body cavity and over 20 mm in width. They are flaccid and bloodshot but, in most instances, they are brownish in colour (Figure 74), rather than wine red, like the ovary. This is probably due to the presence of residual sperm in the testes at this point. The amount of residual sperm may, however, vary considerably from one individual to another.

Towards the end of stage VII, the testis is approximately 2/3 the length of the body cavity and may be reduced to 5 mm in width over its entire length. The testis is brownish and may be firmer, when little residue is present. This greater firmness is related to the contraction of the gonad (thickening and contortions of the connective tissue) now beginning.

Stage VIII

At the beginning of stage VIII (VIIIa), the testis may be the same length as in stage VII (2/3 the length of the body cavity) and 3 mm or more in width. It is generally brownish in colour (Figure 75), but may also include some wine red tints. As at the end of stage VII, the testis is almost empty, since the production of new germ cells is only beginning. However, it may be firmer again (if little residue is present), since gonad contraction generally increases from stage VII to stage VIII (Figures 60 and 61). As stage VIII progresses, the content (volume) of the gonad increases with the production of germ cells and the distinction between stages VII and VIII then becomes more evident.

As in the case of females, stage II and the beginning of stage VIII (VIIIa) are readily distinguished when the wine red colour and striations produced by the blood vessels are evident in the stage VIII specimen. Otherwise, the slightly elongated appearance of the testis in stage VIII (2/3 of the cavity, rather than 1/2 to 2/3), which is probably related to the incomplete contraction of the testis, can be used to establish the distinction, although this parameter involves a substantial margin of error.

At the end of stage VIII (VIIIb), spawning marks are generally difficult to detect; differences in gonad colour are frequently non-existent and the more elongated appearance of the testis in stage VIII has disappeared. The only criterion permitting the distinction of stages VIII and II at this point is testis width, which may be slightly greater in stage VIII (5 to 10 mm, rather than 3 to 8 mm). The distinction between stages III and VIII must also be based on gonad width, which is greater in stage III.

DISCUSSION

Histological classification

As in the case of females, the microscopic descriptions associated with each maturity stage in males (Appendix 2) are similar to those given by Polder (1961) and Bowers and Holliday (1961). The principal difference lies in the fact that the microscopic criteria selected are defined more clearly and that the period corresponding to stage VIII is more thoroughly documented.

From stage III to stage V, maturity staging is somewhat less precise. The maturation of the testes in this phase of development can be related only to a gradual increase in the numbers of spermatozoa in the seminiferous tubules. For instance, spermatozoa occupy one third of the area defined by the seminiferous tubules at the end of stage III and no more than 3/5 by the end of stage V. These divisions make it possible, however, to describe in detail the period corresponding to the principal phase of testicular growth.

As in the case of females, microscopic analysis has enabled us to divide the male reproductive cycle more precisely than is possible with the CAFSAC macroscopic key. This cycle, as we have defined it, includes 11 maturity stages rather than eight. The two parts of stage VIII (VIIIa and VIIIb) are similar to stages IIa and IIb respectively, in terms of germ cell development. The only difference lies in the fact that spermatogonium production is already advanced in the stage II testis, whereas it is just beginning in stage VIIIa. We have chosen to define the beginning of stage VIII as the point at which groups of primary germ cells are present in the majority of the seminiferous tubules. This criterion is more objective than an arbitrary estimate of the proportion of spermatogonia to primary germ cells, as used to distinguish stages I and II. This decision creates a slight disparity between stages II and VIII in the male, in contrast to the situation with respect to females.

Stage VIII has been subdivided into only two parts, compared to three for females, because of the difficulty associated with establishing a precise distinction between the various phases of the spermatogenic cycle and its extreme rapidity, once initiated. Stage III could not be divided into two parts since such a subdivision would have involved overly imprecise estimates of the quantity of spermatozoa in the seminiferous tubules. As in the case of females, individuals classified in stage VIII in June may belong to either one of the two spawning groups. The subdivision of stage VIII males has enabled McQuinn (1989) to distinguish the spawning groups during this critical period.

The subdivision of stage V into two parts (Va and Vb) cannot be used to distinguish the spawning groups. However, it can help to define the precise level of testicular maturation when the males arrive on the spawning grounds.

Macroscopic classification

The macroscopic method of identifying sexual maturity stage is even less precise in males than in females, since egg characteristics (visibility, diameter and opacity) can facilitate the staging process in the latter. In most instances, the degree of maturation achieved by the testis must be classified on the basis of gonad dimensions. This is true in particular of the separation of stages I to IV, which is based on an assessment of gonad width and of their length in relation to the body cavity, and of the recognition of stage V, in which the testes occupy the entire volume of the body cavity of the fish.

The improvements to be made to the CAFSAC key relate primarily to the definition of the priority to be assigned to the various criteria for use in the field (Appendix 3). For instance, the CAFSAC key notes that the separation of stages III, IV and V is based primarily on an assessment of gonad dimensions, in the case of frozen samples. According to our observations, gonad dimensions should be used with fresh samples as well. This difference is probably related to the fact that the CAFSAC classification considers colour a valid criterion for distinguishing these stages in the case of fresh specimens.

The values for relative gonad length should be added to the CAFSAC key, which mentions this parameter only in association with stage IV. As in the case of females, it is quite probable that the testicular volumes given in the CAFSAC key

for stage III (testes occupying approximately half the central cavity) do not reflect all the possibilities which may be encountered at this stage. We give gonad volume only for stage V (100% of the volume of the body cavity). The additional information provided by the gonad volume values for each maturity stage may be even more important in the case of males, since staging is generally based solely on the width and relative length of the gonads. However, the use of gonad volume would also involve a sizable margin of error.

Classification of stage VI does not generally constitute a problem. However, certain precisions should be made. For instance, Cleary et al. (1982; Appendix 1) recognized that the viscous appearance of the gonad in stage VI may be related to the condition of the specimen. Dilation of the sperm duct should therefore be added to the CAFSAC key's definition of stage VI, since this criterion is more reliable than the viscous appearance of the gonad.

The description of stage VII given in the CAFSAC classification applies very well to specimens immediately after spawning, but fails to take into account the changes experienced during the subsequent period of gonad reconstruction. At the end of stage VII, the testes are generally still almost empty, but they are contracted and firmer in comparison to the beginning of this stage. They continue to become firmer during stage VIII and the contents of the testis gradually increase. The increase in testis contents can be used to separate stages VII and VIII, but does not become evident until well into stage VIII. On the transition between these two stages, only the greater contraction and firmness of stage VIII gonads permit their distinction from stage VII. Although these changes are difficult to detect, they should nonetheless be added to the CAFSAC key.

As in the case of females, the statement made in the CAFSAC key that the testes are firmer in stage VIII than in stage II is erroneous. The separation between the beginning of stage VIII and stage II should be based, instead, on the wine red colour, which may be more pronounced in stage VIII. When these differences are not evident (with most frozen specimens), the distinction must be based, as in the case of females, on the relative length of the gonad, which is slightly greater at the beginning of stage VIII (over 2/3 the length of the body cavity, rather than 1/2 to 2/3). At the very end of stage VIII, only gonad width can be used to distinguish stages II, III and VIII. For instance, the stage VIII testis may be slightly wider than in stage II and narrower than in stage III. However, the gonad width values listed for these stages (appendix 3) indicate a substantial overlap. The distinction between stages II, III and VIII remains the principal area of difficulty in the macroscopic method of determining maturity stages in the male.

CONCLUSION

Comparison of the microscopic and macroscopic descriptions for each maturity stage has provided the opportunity for improvements to the CAFSAC key. The period of gonad reconstruction has been more fully documented and further precisions have been provided on the priority to be assigned to the various criteria for use in the field. For example, gonad colour, which is mentioned regularly in the CAFSAC classification, should be used only for the separation of stages VIII (generally only the beginning of stage VIII) and II, even in the case of fresh samples. Although this study was performed entirely with fresh samples, the recommended criteria apply generally to frozen samples since, in most cases, classification of maturity stage must be based on an assessment of gonad dimensions in relation to those of the fish. This observation applies in particular to males, since egg characteristics facilitate the identification of certain maturity stages in the female.

The gonad width values mentioned in this study do not take into account variations associated with the size of the fish. The modifications made to the CAFSAC key within the framework of this study thus do not always serve to reduce the lack of precision in the CAFSAC key, but do permit its uniform application.

The macroscopic method of determining sexual maturity will continue to be open to serious errors, which will affect the relevance of the data relating to the separation of the spawning groups. The microscopic method permits more precise and objective definition of the various maturity stages. In addition, it offers the possibility of further subdividing the reproductive cycle of the herring (12 stages in females and 11 in males). This histological study has been used as the basis for a study by McQuinn (1989), designed to develop a method of separating the spawning groups on the basis of maturity stage, determined indirectly through the use of a gonadosomatic index. For instance, the subdivisions of stages VIII and III have enabled McQuinn (1989) to resolve some of the problems associated with the overlapping of maturity stages of the spawning groups at certain periods of the year.

Finally, the precise histological criteria associated with each maturity stage make this study a reliable identification guide permitting uniform application. This guide can thus be used in other studies requiring precise assessments of maturity stage. For instance, it offers the possibility of studying in greater detail the duration of the various maturity stages in each of the spawning groups. Such a study is recommended, to permit more accurate assessment of those periods of the year and maturity stages when overlapping between the two stocks occurs.

REFERENCES

Baker, J R. 1950. Cytological technique. Methuen, London, 131 p.

Baxter, I G. 1959. Fecundities of winter-spring and summer-autumn herring spawners. J Cons int Explor Mer 25(1): 73-70.

Bowers, A B and F G T Holliday. 1961. Histological changes in the gonad associated with the reproductive cycle of the herring (Clupea harengus L). Mar Res 5: 1-20.

Broch, H. 1908. Norwegische Heringsuntersuchungen wahrend der Jahre 1904-1906, Bergens Museums Aarbok, No 1: 69 p.

Bruslé, J and S Bruslé. 1983. La gonadogénèse des poissons. Reprod Nutr Dev 23(3): 453-491.

Cleary, L, J J Hunt, J Moores and D Tremblay. 1982. Herring aging workshop, St John's, Newfoundland, March 1982. CAFSAC Res Doc 82/41, 10 p.

Day, L R. 1957. Populations of herring in the southern Gulf of St Lawrence. Bull Fish Res Bd Can No 111, 121-137.

Foley, J O. 1924. The spermatogenesis of Umbra limi. Biol Bull 50: 117-146.

Gokhale, S V. 1957. Seasonal histological changes in the gonads of the whiting (Gadus merlangus L) and the Norway Pout (G esmarkii Nilsoon). Indian J Fish 4: 92-112.

Grier, H J, J M Fitzsimmons and J R Linton. 1978. Structure and infrastructure of the testis and sperm formation in Goodeid teleosts. J Morph 156(3): 419.

Haegele, C W and J F Schweigert. 1985. Distribution and characteristics of herring spawning grounds and description of spawning behaviour. Can J Fish Aquat Sci 42 (Suppl 1): 39-55.

Heincke, Fr. 1898. Naturgeschichte des Herrings. Teil I - Die Lokalformen und Wanderungen des Herrings in den europaischen Meeren. Abh Dtsch Seefisch Ver 2, 128-223.

Johansen, A C. 1924. On the summer and autumn spawning herrings of the North Sea. Medd Komm Havunders Ser Fisk, 7(5), 119 p.

Khoo, K H. 1979. The histochemistry and endocrine control of vitellogenesis in goldfish ovaries. Can J Zool 57: 617-626.

Lea, E. 1910. On the methods used in herring investigations. Report on Herring Investigations by Johan Hjort. Cons Perm Intern Explor Mer. Publications de Circonstance, No 53, p 35.

Le Moigne, A. 1979. Abrégé de biologie du développement. Masson, Paris, 224 p.

McQuinn, I H. 1989. Identification of spring- and autumn-spawning herring (Clupea harengus harengus) using maturity stages assigned from a gonadosomatic index model. Can J Fish Aquat Sci 46 (6): 969-980.

Naumov, V M. 1956. The ovogenesis and ecology of the sexual cycle of the Murmansk herring (Clupea harengus harengus L). Trans Knipovich polyar Sci Inst 9: 176-225 (translated from the Russian in Spec Sci, Reprod Fish, U S Fish and Wildlife Serv, 327: 203-262, 1959).

Polder, J W. 1961. Cyclical changes in testis and ovary related to maturity stages in the North Sea herring (Clupea harengus L). Neth J Zool, 14: 45-60.

Turner, C L. 1919. The seasonal cycle in the perch spermary. J Morph 32: 681-711.

Wallace, R A and K Selman. 1977. Oogenesis in Fundulus heteroclitus. I. Preliminary observations on oocyte maturation in vivo and in vitro. Develop Biol 62(2): 354-369.

Williamson, H C. 1945. Development of the roe and milt of the herring. Independent Lives. Fish News, Oct 6, 1945, p 10.

Yamamoto, K. 1956. Studies on the formation of fish eggs. VII: The fate of the yolk vesicles in the oocytes of the herring, Clupea pallasii. Annot Zool Japan, 29: 91-96.

PLATES AND FIGURES

LIST OF ABBREVIATIONS USED

Females

Ap - Primary artery
Bc - Band of connective tissue
Cg - Granulosa
Ch - Chorion
Cm - Centre layer of chorion
Cn - Inner layer of chorion
Cx - Outer layer of chorion
Cy - Cytoplasm
Es - Space between lamellae
Fo - Follicle
Gv - Yolk globule
Hm - Hematoma
Jo - Young oocyte
No - Nucleus
Nu - Nucleolus
Od - Resting oocyte
Og - Oogonium
Or - Mature egg in process of resorption
Os - Maturing oocyte (without yolk)
Ov - Oocyte beginning vitellogenesis
Po - Ovarian wall
Th - Theca
Vp - Primary vein
Vs - Blood vessels
Vv - Yolk vesicle

Males

Ap - Primary artery
Cc - Connective cell
Cy - Cytoplasm
Fl - Flagellum
Gp - Primary germ cell
Hm - Hematoma
No - Nucleus
Nu - Nucleolus
Pt - Testicular wall
R - Residue
Sc - Spermatocyte
Sp - Spermatogonium
Sm - Sperm duct
Sr - Residual sperm
Sz - Spermatozoa
Tb - Tubule wall
Tc - Connective tissue
Vp - Primary vein
Vs - Blood vessels

PLATE I

STAGE I

Fig 2 Beginning of stage I. Oocytes are present in small numbers, with the theca as the only follicular layer. The ovarian wall is thin and may consist only of its outer membrane. Transverse section. x 180.

Fig 3 End of stage I. The ovary contains more oocytes than at the beginning of stage I and its vascular system shows further ramification. In longitudinal section, the lamellar structure and bands of connective tissue extending across the gonad are more evident. x 40.

Fig 4 Stage I. Detailed view of an oogonium, after the description by Bowers and Holliday (1961). These cells vary in diameter from 10 to 14 µm and have a nucleolus located in the centre of the nucleus. x 1000.

Fig 5 Stage I. Detailed view of an oocyte, after the description by Bowers and Holliday (1961). The nucleoli of the oocytes are dispersed around the periphery of the nucleus. The theca is the only follicular layer apparent. x 1000.

PLATE II

STAGE II

Fig 6 Formation of the granulosa layer begins and the first yolk vesicles appear around the periphery of the oocyte. In the early stages of formation, the granulosa is more difficult to distinguish, because its cells are flattened, distant from one another and pressed against the theca. Microphotograph of stage VIII, but oocyte development is the same for the beginning of stage II (IIa). x 250.

Fig 7 Beginning of stage II (IIa). Formation of the yolk vesicles has begun in most of the oocytes. The vesicles appear first around the periphery of the cell. Some cells do not yet contain yolk, but their lighter coloured cytoplasm indicates that the granulosa is developing and thus that they have begun the maturation phase. x 32.

Fig 8 Beginning of stage II (IIa). The yolk vesicles form a wide band around the periphery of the oocytes. Their presentation in the form of white vacuoles is related to the weak reaction of the vesicles to hematoxylin and eosin staining (Khoo, 1979). As stage II progresses, it becomes easier to distinguish the resting oocytes from those in the process of maturation. x 100.

Fig 9 End of stage II (IIb). Production of the yolk globules begins. The centre layer of the chorion can be distinguished. x 1000.

PLATE III

STAGE III

Fig 10 Beginning of stage III (IIIa). The yolk globules form a wide band around the periphery of the oocytes. This figure shows the transition between stages IIIa and IIIb, with the globules beginning to invade the portion of the oocyte cytoplasm adjacent to the nucleus. x 250.

Fig 11 End of stage III (IIIb). The yolk globules have invaded the central portion of the oocyte cytoplasm, but in most of the cells the nucleus is clear of yolk globules. In this figure, the yolk vesicles are still present throughout the cytoplasm of the cell. Large hematomas can occasionally be observed in the gonad. They may be due to the poor condition of the ovary and give it a wine red appearance (see figure 35). x 44.

Fig 12 End of stage III (IIIb). The yolk globules are present throughout the cytoplasm of the cell, with the vesicles located primarily around the periphery. This figure shows the transition between stages IIIb and IV, with the yolk globules pressed against the nuclei of some oocytes. However, examination of numerous oocytes has confirmed that this specimen belongs to stage IIIb. x 90.

Fig 13 Beginning of stage III (IIIa). The centre and outer layers of the chorion become more readily discernible. The striations of the outer layer are also more evident. x 1000.

PLATE IV

STAGES IV AND V

Fig 14 Stage IV. The yolk globules are pressed against the nuclei of the oocytes. x 70.

Fig 15 Stage IV. The three layers of the chorion, including the inner layer, are now readily identifiable. x 1000.

Fig 16 Stage V. Decentralization of the nucleus begins. The oocytes are still surrounded by their follicles. x 36.

Fig 17 Stage V. Towards the end of stage V, fusion of the yolk globules becomes more pronounced and the nucleus of the cell is no longer apparent. The oocytes are still surrounded by their follicles. x 38.

PLATE V

STAGES VI AND VII

Fig 18 Stage VI. The ovulated eggs are in the centre of the ovary, while the empty follicles and resting oocytes are generally found around the periphery. x 32.

Fig 19 Stage VII. Detailed view of a young oocyte, surrounded by its theca, together with an empty follicle and a blood vessel. Observation of empty follicles constitutes one of the conclusive indications of previous spawning. x 200.

Fig 20 Stage VII. After spawning, the ovarian wall and bands of connective tissue are thick and contorted, and numerous empty follicles and hematomas are present in the ovary. x 32.

Fig 21 Stage VII. In some cases, hematomas are almost non-existent in the ovary and the empty follicles are not readily apparent. The principal indication that spawning has taken place in this case is the thickening and contortions of the ovarian wall, together with the absence of lamellar structure. x 32.

PLATE VI

STAGES VII AND VIII

Fig 22 Stage VII. The lamellar structure of the ovary redevelops as new oocytes are produced. In this figure, the lamellae are still absent from the central portion of the ovary. The ovarian wall gradually becomes thinner and less contorted. Resorption of the mature eggs is not far advanced at the end of stage VII and the presence of one of these eggs represents clear evidence of previous spawning. Young oocytes (diameter approximately 15 µm) can be observed in the ovary at this stage. x 32.

Fig 23 Beginning of stage VIII (VIIIa). Lighter coloured oocytes can now be observed in the ovary. x 76.

Fig 24 Beginning of stage VIII (VIIIa). Vitellogenesis has not yet begun, but most of the oocytes have lighter coloured cytoplasm. Some spawning marks are already less evident: the ovarian wall is thinner, empty follicles are no longer apparent and the lamellar structure has redeveloped. However, open spaces remain between the lamellae. These spaces are probably related in part to the condition of the histological section, but also to incomplete reconstruction following spawning. x 32.

Fig 25 Beginning of stage VIII (VIIIa). Vitellogenesis is beginning in some oocytes, but not in a large enough proportion to permit classification of this specimen in stage VIIIb. Indications of previous spawning are still apparent; the ovarian wall is thick, there are pronounced hematomas (enlargement too small to show the red globules) and wide empty spaces remain between the connective tissue lamallae. x 32.

PLATE VII

STAGE VIII

Fig 26 Beginning of stage VIII (VIIIa). Vitellogenesis has not yet begun. No hematomas are apparent, but the presence of a mature egg in the process of resorption and the thickening and contortions of the ovarian wall and of the bands of connective tissue represent clear indications of previous spawning. x 32.

Fig 27 Middle of stage VIII (VIIIb). Most of the oocytes have a wide band of yolk vesicles around the periphery of their cytoplasm, but the yolk globules are not yet apparent. In this case, the only identifiable spawning marks are the presence of a few prominent blood vessels and the marked spacing between the connective tissue lamallae. x 32.

Fig 28 Middle of stage VIII (VIIIb). The yolk vesicles are well established, but production of yolk globules has not yet begun. Extensive hematomas (enlargement too small to show the red globules) are present and the ovarian wall is thick. x 32.

Fig 29 End of stage VIII (VIIIc). Beginning of production of the yolk globules. The spacing between the connective tissue lamallae is evident and hematomas (enlargement too small to show the red globules) are still apparent in the ovary. x 32.

PLATE VIII

STAGE VIII (MICROSCOPIC) AND II (MACROSCOPIC)

Fig 30 End of stage VIII (VIIIc). Beginning of production of yolk globules. The ovary is about to pass into stage III, but thickening of the ovarian wall is still pronounced. Hematomas (enlargement too small to show the red globules), probably accentuated by the poor condition of the specimen, remain pronounced. x 32.

Fig 31 Stage II (corresponding to microscopic stage IIa). Ovary golden yellow, between 3 and 5 mm wide and occupying half the length of the body cavity. In this photograph, the incorrect alignment of the posterior end of the gonad with the beginning of the body cavity makes the relative length of the ovary appear to be more than half that of the body cavity.

Fig 32 Stage II (corresponding to microscopic stage IIb). Gonad orange, 5 to 8 mm wide and over half the length of the body cavity.

Fig 33 Stage II (corresponding to microscopic stage IIb). Eggs transparent and difficult to detect with the naked eye.

PLATE IX

STAGE III

Fig 34 Stage III (corresponding to microscopic stage IIIa). Gonad orangey yellow, 5 to 12 mm wide and occupying 2/3 the length of the body cavity.

Fig 35 Stage III (corresponding to microscopic stage IIIb). The presence of hematomas (see figure 11) in some ovaries in poor condition gives them a wine red colour.

Fig 36 Stage III (corresponding to microscopic stage IIIa). Eggs transparent and readily visible to the naked eye.

Fig 37 Stage III (corresponding to microscopic stage IIIb). The orange tints gradually fade during stage III. By the end of this stage, the ovary is generally golden yellow in colour.

PLATE X

STAGES IV, V AND VII

Fig 38 Stage IV. The gonad is light yellow, the same length as the body cavity and may be over 20 mm wide.

Fig 39 Stage V. Ovary light yellow, same length as the body cavity and up to 30 mm wide. Placed in the body cavity, stage V ovaries occupy the entire volume.

Fig 40 Stage V. Towards the end of stage V, the ovary takes on a brownish colouring which appears to coincide with the marked fusion of the yolk globules preceding ovulation.

Fig 41 Stage VII. At the beginning of stage VII, the gonad may be as long as the body cavity and from 10 to 20 mm wide. It is flaccid, almost empty and wine red in colour.

PLATE XI

STAGES VII AND VIII

Fig 42 Stage VII. At the end of stage VII, the ovary may be between 5 and 10 mm wide and approximately 2/3 the length of the body cavity. It is almost empty, but firmer than at the beginning of stage VII, probably because of the thickening of the connective tissue. In this figure, the ovary shows yellow tints at its posterior end.

Fig 43 Stage VIII (corresponding to microscopic stage VIIIa). The gonad occupies over 2/3 the length of the body cavity and is approximately 5 mm wide. The posterior end is wine red in colour and the anterior end orangey yellow. The ovary is cylindrical in appearance.

Fig 44 Stage VIII (corresponding to microscopic stage VIIIa). The cylindrical shape of the ovary is related to the presence of larger numbers of eggs. These eggs remain difficult to distinguish with the naked eye.

Fig 45 Stage VIII (corresponding to microscopic stage VIIIb). Ovary between one half and 2/3 the length of the body cavity and between 3 and 8 mm wide. The colouring changes gradually from wine red to orangey yellow.

PLATE XII

STAGES I AND II

Fig 47 Stage I. The primary germ cells and spermatogonia are the only germ cells present. The seminiferous tubules are not yet formed; the connective tissue is distributed in a loose network of fibres throughout the gonad. Microphotograph taken using a mercury lamp. x 200.

Fig 48 Stage I. Detailed view of the primary germ cells and spermatogonia. The former are larger in diameter (up to 15 µm) than the spermatogonia (approximately 8 µm), but the arrangement of the chromatin and nucleolus is the same for both cell types (Bowers and Holliday, 1961). This arrangement seems less evident, however, in the spermatogonia, probably because of the more compact appearance of their nuclei. Microphotograph taken using a mercury lamp. x 1000.

Fig 49 Beginning of stage II (IIa). The spermatogonia represent the most advanced phase of spermatogenesis found in the testis. The proportion of spermatogonia to primary germ cells is greater than in stage I. The organization of the connective tissue into seminiferous tubules is better defined than in stage I, but remains incomplete. Microphotograph taken using a mercury lamp. x 400.

Fig 50 End of stage II (IIb). As the spermatogonia increase in number, they form distinct groups around the periphery of the seminiferous tubules. Groups of primary spermatocytes are found primarily in the central portion of the seminiferous tubules. The structure of the latter remains incomplete. x 256.

PLATE XIII

STAGES II, III AND IV

Fig 51 End of stage II (IIb). The first spermatozoa appear in a few seminiferous tubules. x 50.

Fig 52 Stage III. The spermatozoa are located in the centre of the seminiferous tubules, while groups of less mature cells are found around their periphery. The spermatozoa occupy no more than one third of the area defined by the seminiferous tubules. In this figure, the seminiferous tubules are well defined. Microphotograph taken using a mercury lamp. x 100.

Fig 53 Stage III. The spermatozoa occupy no more than one third the area of the seminiferous tubules. In this figure, the structure of the tubules is not yet clearly defined. This phenomenon is probably related primarily to the histological section (crumbling and poor orientation of the section), but could also be caused by as yet incomplete reconstruction of the testis following spawning (see stage VIII). This possibility is supported by the presence of prominent blood vessels. x 100.

Fig 54 Stage IV. The central band of spermatozoa (including a number of spermatids) covers up to 3/5 the area of the seminiferous tubules. The narrow band of maturing germ cells located around the periphery of the tubules consists primarily of spermatocytes. Microphotograph taken using a mercury lamp. x 200.

PLATE XIV

STAGES V AND VI

Fig 55 Beginning of stage V (Va). The seminiferous tubules contain only spermatids and spermatozoa. The spermatozoa remain attached to the Sertoli cells (Grier et al., 1978) and thus continue to resemble dense packets of nuclei, separated by open spaces containing the flagella. Microphotograph taken using a mercury lamp. x 200.

Fig 56 Beginning of stage V (Va). The heads of the spermatozoa form dense packets, while the flagella float freely. Microphotograph taken using a mercury lamp. x 1000.

Fig 57 End of stage V (Vb). The testis contains only spermatozoa, which are distributed evenly through the seminiferous tubules. Microphotograph taken using a mercury lamp. x 200.

Fig 58 Stage VI. Loosening of the contents from the walls of the seminiferous tubules marks the passage from stage V to stage VI. This loosening leads to a thickening of the testicular and tubule walls. Microphotograph taken using a mercury lamp. x 100.

PLATE XV

STAGES VII AND VIII

Fig 59 Stage VII. In some cases, the seminiferous tubules contain almost no residue, but the testicular and tubule walls are thick and contorted. The structure of the seminiferous tubules is altered, but still apparent. Prominent blood vessels are also visible.

Fig 60 Stage VII. Residue from the previous spawning are present in abundance. The connective cells form a band along the tubule walls. These walls are contorted, making the structure of the seminiferous tubules difficult to distinguish. Germ cells are present in small numbers and are difficult to observe. Microphotograph taken using a mercury lamp. x 100.

Fig 61 Beginning of stage VIII (VIIIa). Division of the primary germ cells has begun. These are found in readily observable groups throughout the connective cells, which are still numerous. The residue has been almost completely resorbed. Contraction of the tubule walls is very evident. x 100.

Fig 62 Beginning of stage VIII (VIIIa). The spermatogonium multiplication phase has begun and spermatogonia now occupy a good portion of the seminiferous tubules. A few primary germ cells (in which division is continuing) are also present. The tubule walls are still thick and contorted and may contain prominent blood vessels. The residue has been completely resorbed. Microphotograph taken using a mercury lamp. x 100.

PLATE XVI

STAGE VIII

Fig 63 Beginning of stage VIII (VIIIa). In some instances, a substantial band of spermatogonia is present along the tubule walls, but residue is still present in abundance within the seminiferous tubules. Microphotograph taken using a mercury lamp. x 200.

Fig 64 End of stage VIII (VIIIb). The spermatogonia have passed into the other phases of the spermatogenic cycle, but spermatozoa are not yet accumulating in the central portion of the seminiferous tubules. Contraction of the tubule walls is still apparent.

Fig 65 End of stage VIII (VIIIb). Spermatozoa are present in some seminiferous tubules, although in small numbers. Contraction of the tubule walls is still evident.

PLATE XVII

STAGES I, II AND III

Fig 66 End of stage I. The testis is less than half the length of the body cavity and a maximum of 3 mm in width. Its brownish (rather than wine red) colour, flat (rather than cylindrical) appearance and rounded (rather than pointed) anterior end permit differentiation at this point from the ovary.

Fig 67 Stage II (corresponding to microscopic stage IIb). In this figure, the length of the gonad is less than half the length of the body cavity, but generally the relative length of the gonads in stage II is between half and 2/3 of the body cavity. Their width varies between 3 and 8 mm and they are brownish in colour.

Figs 68 69 Stage III. The relative length of the gonad may vary considerably in stage III. In some instances, it may be only half that of the body cavity (Figure 68), but generally it occupies approximately 2/3 of the central cavity (Figure 69). It is 5 to 10 mm in width at the posterior end and 10 to 20 mm at the widest point. It may be pinkish grey in colour.

PLATE XVIII

STAGES III, IV AND V

Fig 70 Stage III. In some instances, the colour may be wine red.

Figs 71 72 Stage IV. The testes are generally as long as the body cavity (figure 71), but some exceptions may be observed (Figure 72; testis not as long as the body cavity). Width is over 10 mm at the posterior end and may exceed 20 mm at the widest point. The whitish tints become more accentuated during stage IV.

Fig 73 Stage V. The testis now occupies the entire volume of the body cavity. It is milky white in colour and the sperm duct is swollen for its entire length, allowing sperm to escape when pressure is applied.

PLATE XIX

STAGES VII AND VIII

Fig 74 Stage VII. The testis is almost empty. It is over 20 mm in width and over 2/3 the length of the body cavity. Its brownish colour is produced by the combination of the wine red tints of the blood vessels and the whitish tints of the residual sperm.

Fig 75 Stage VIII (corresponding to microscopic stage VIIIa). The testis is brownish and remains almost empty, since spermatogonium production is just beginning. It can, however, be distinguished from stage VII by its greater firmness, related to the increasing contraction of the gonad.

Fig 76 Stage VIII (corresponding to microscopic stage VIIIb). The testis may be as much as 10 mm in width. In this figure, the brownish colour is still evident. However, at this maturity level, the testes frequently no longer show these tints.

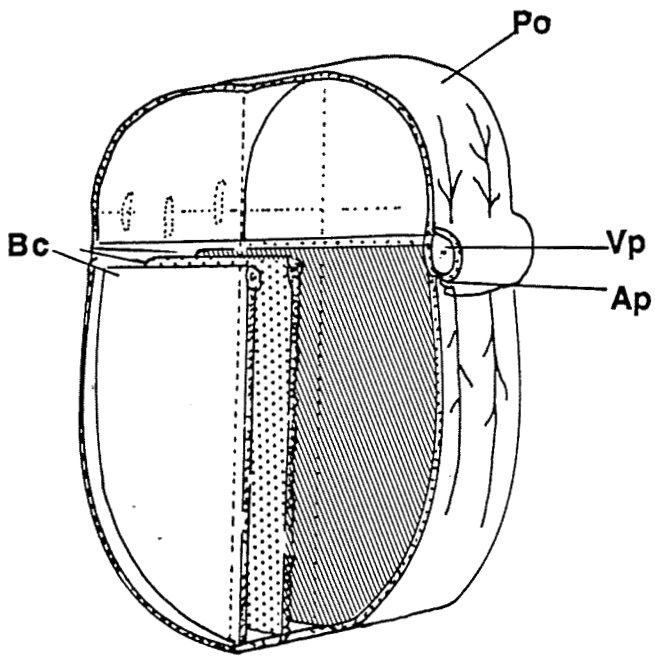

Figure 1 Schematic representation of ovarian infrastructure. The ovary consists of a wall from which a series of bands of connective tissue develop, extending across the gonad and acting as supports for the germ cells. The vascular system consists primarily of one vein and one artery, running the full length of the gonad (after Polder, 1961).

PLANCHE I

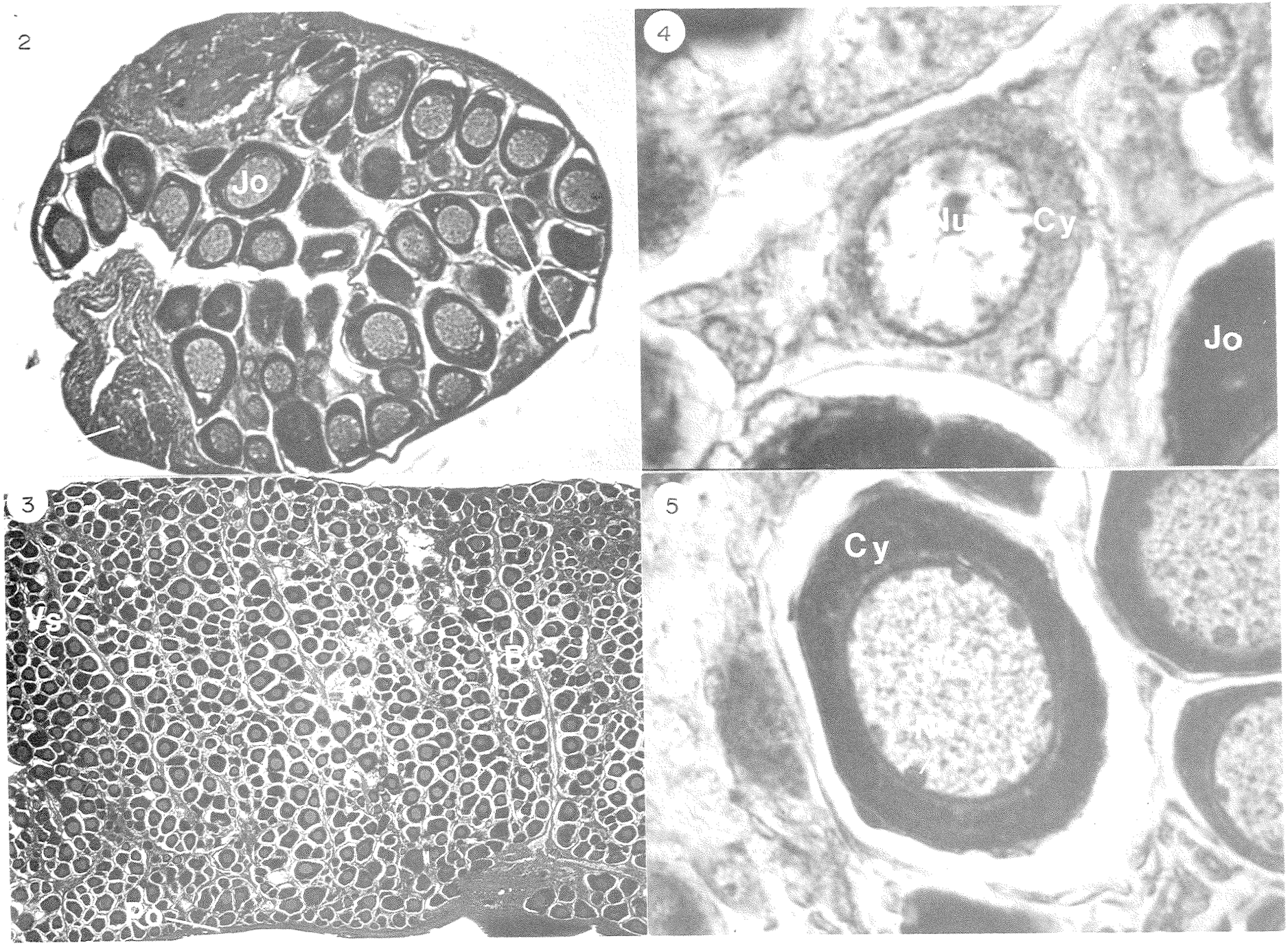

PLANCHE II

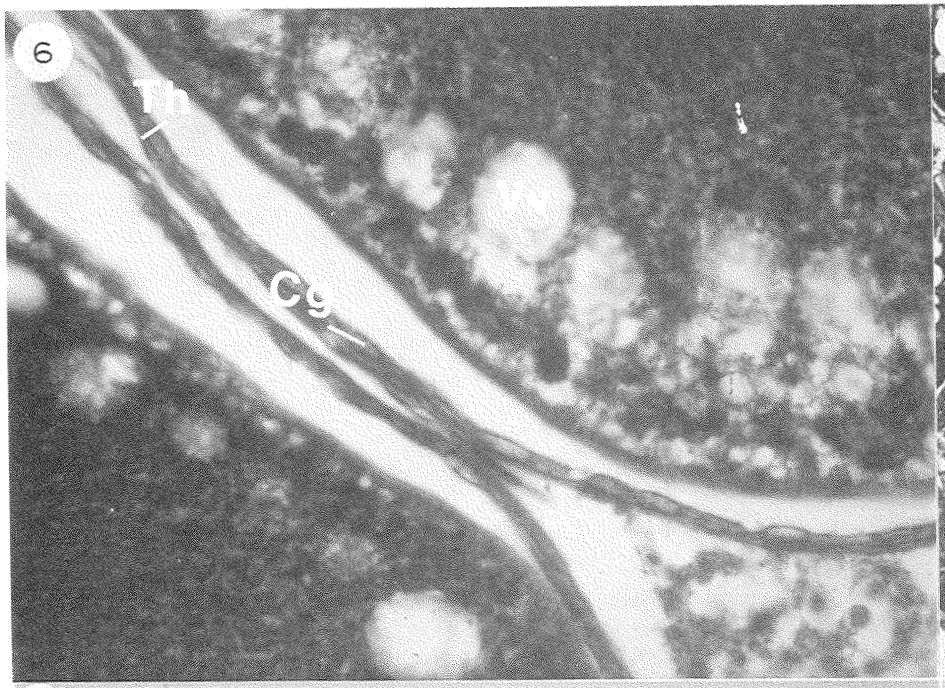

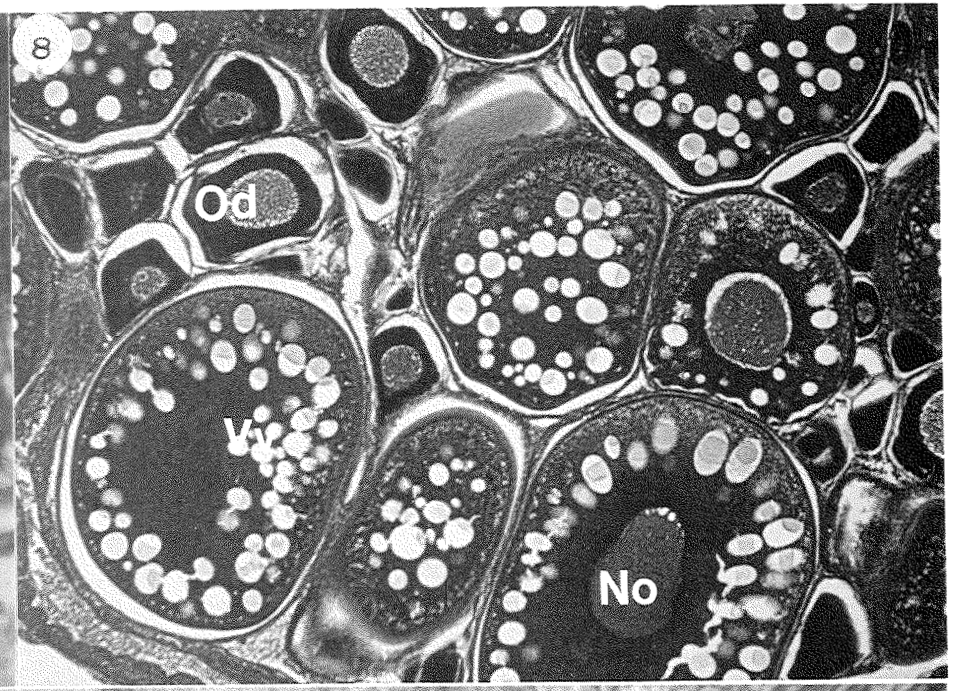

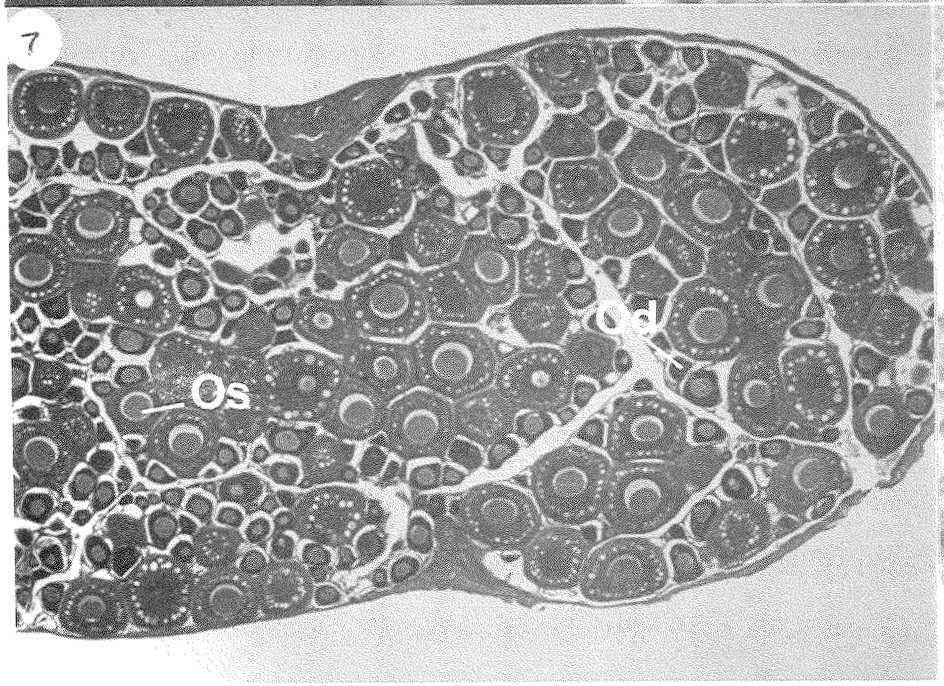

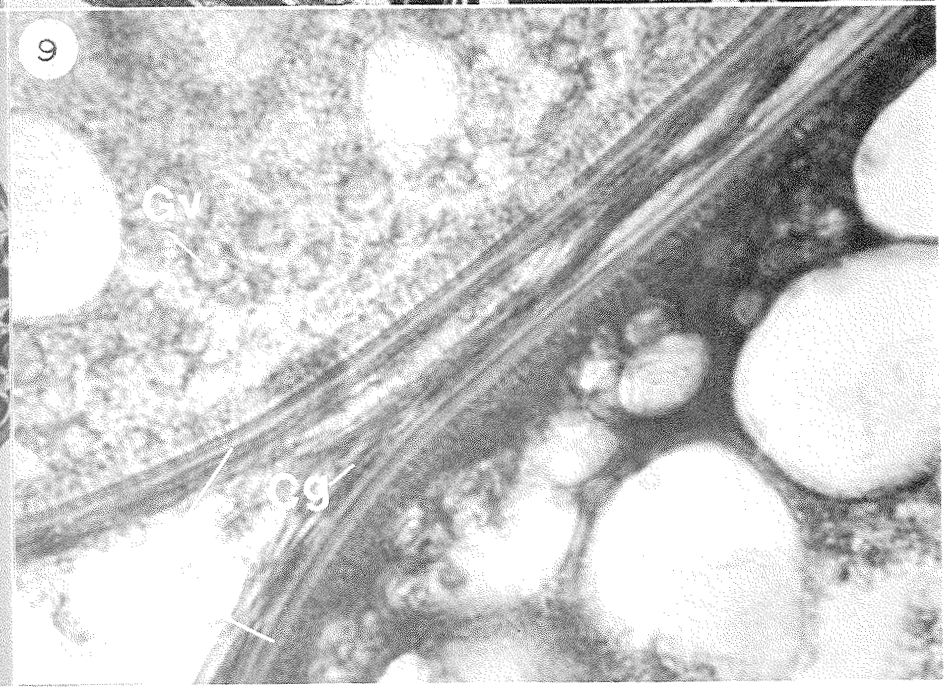

PLANCHE III

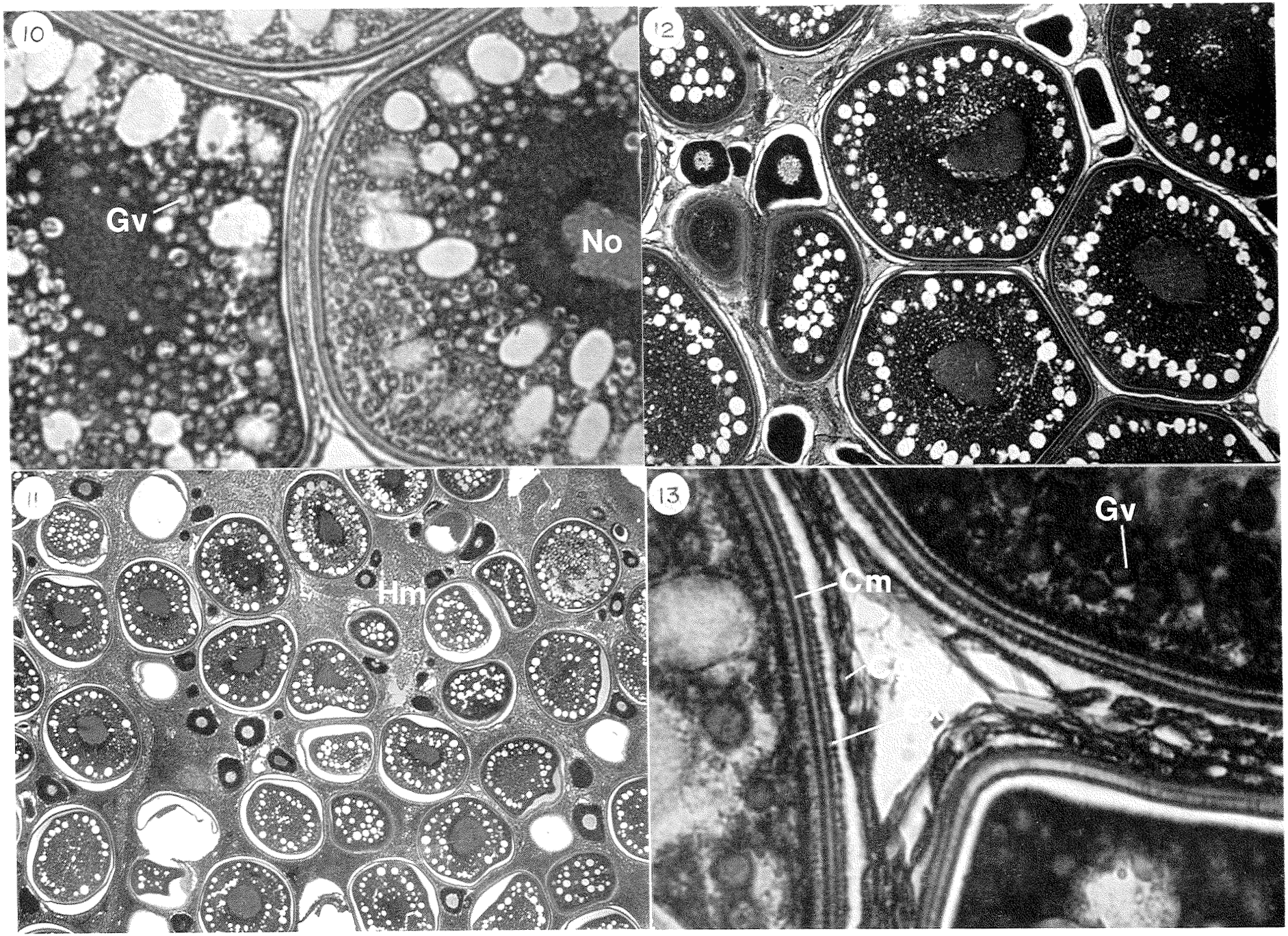

PLANCHE IV

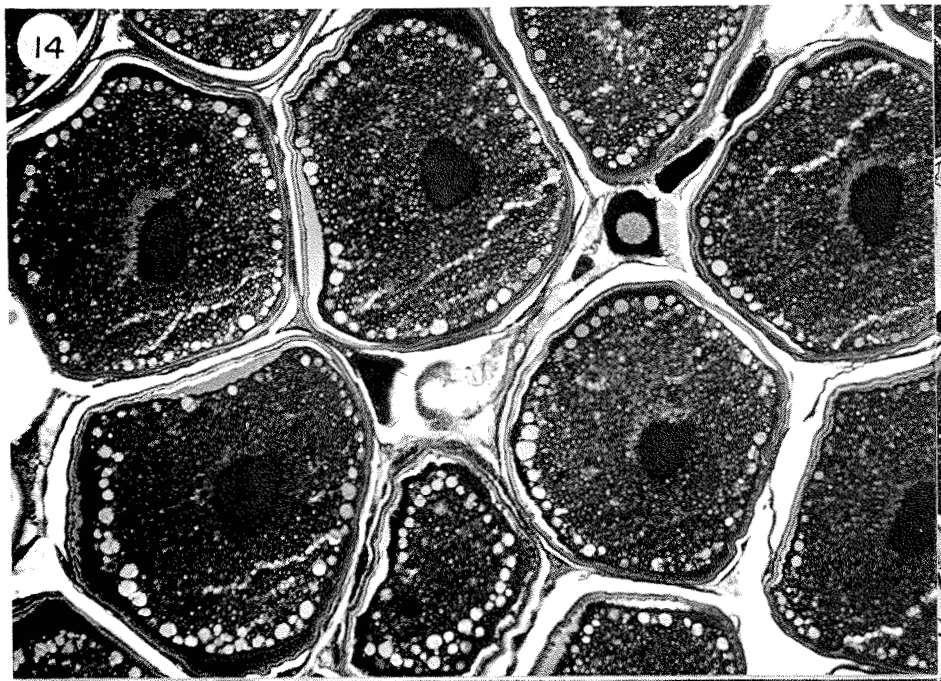

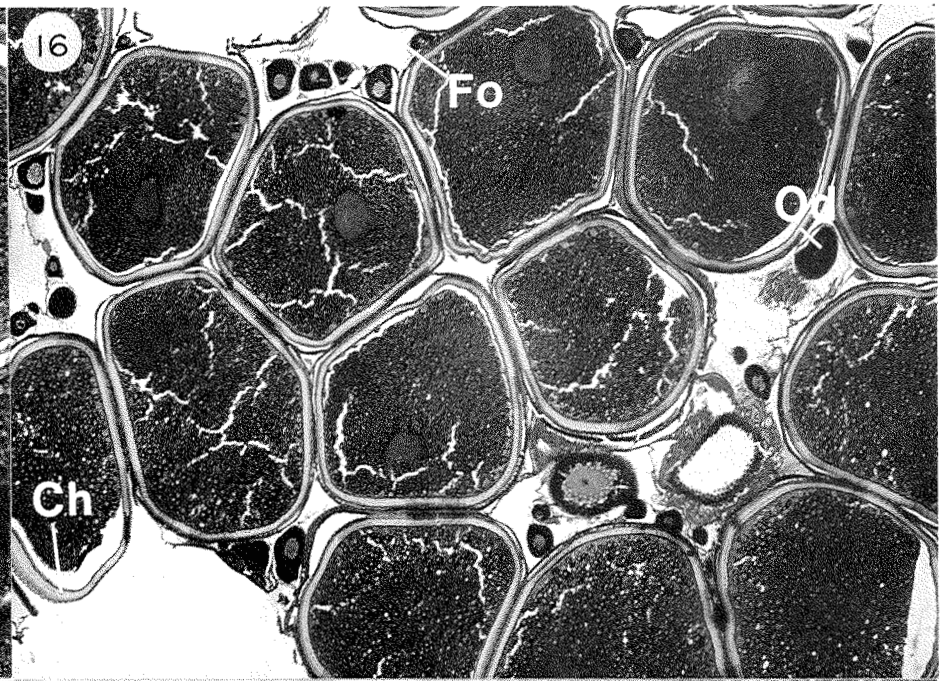

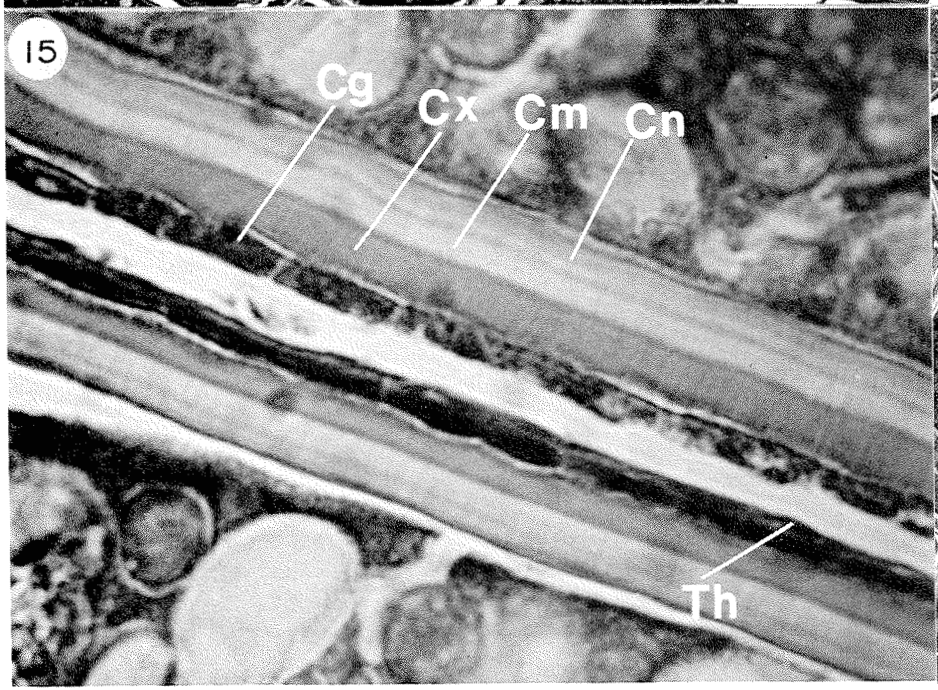

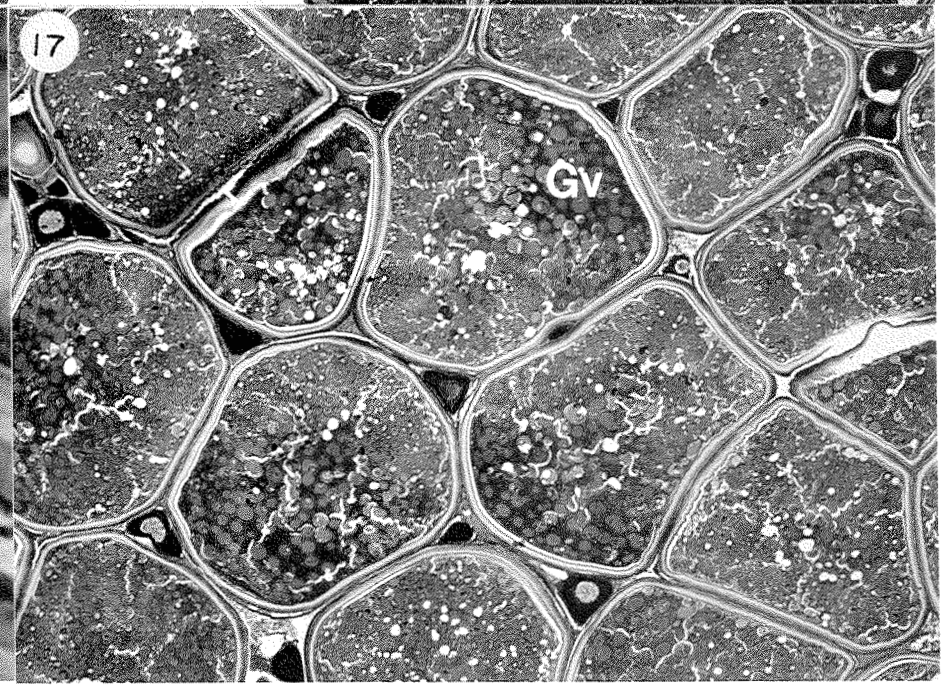

PLANCHE V

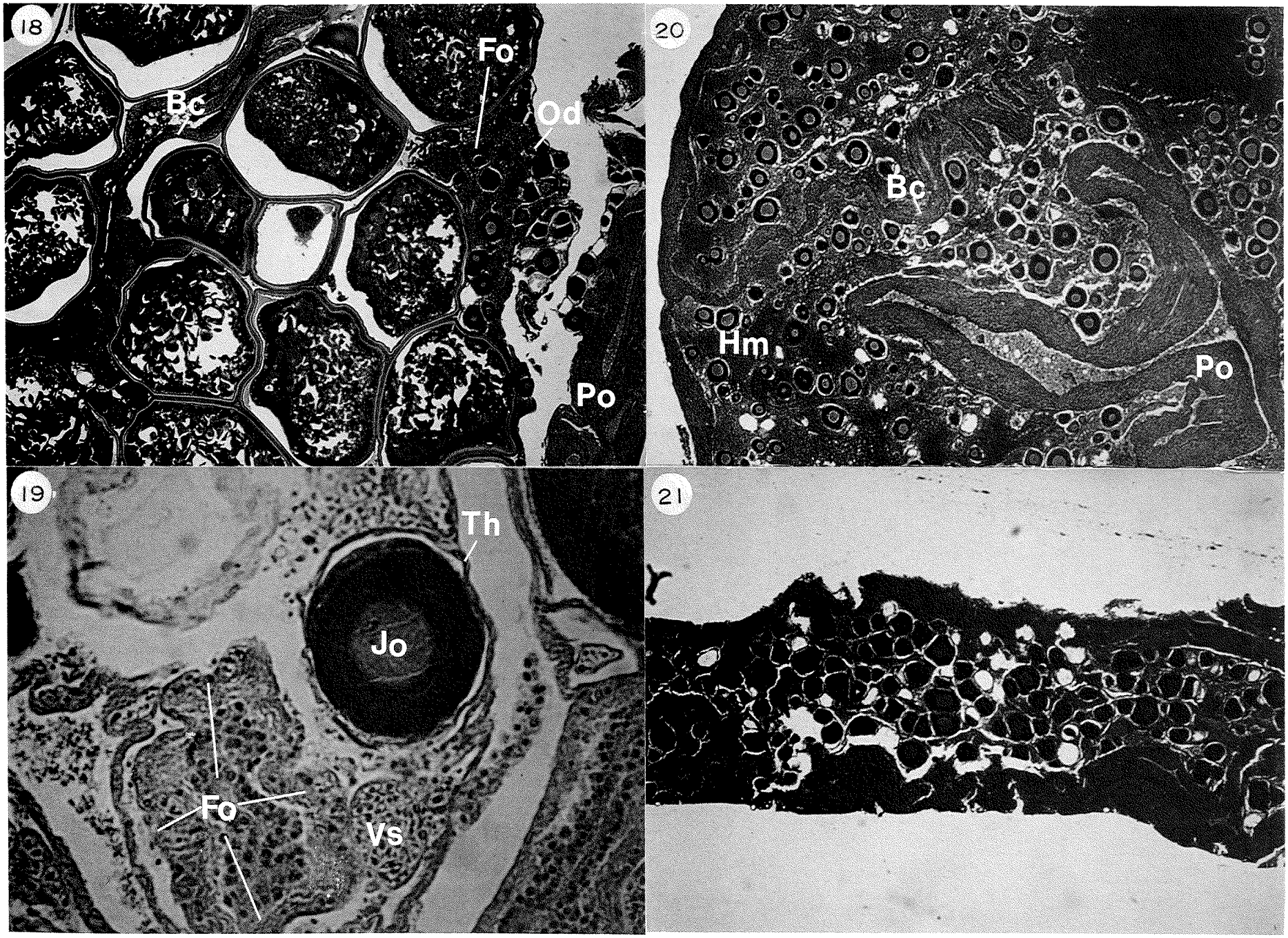

PLANCHE VI

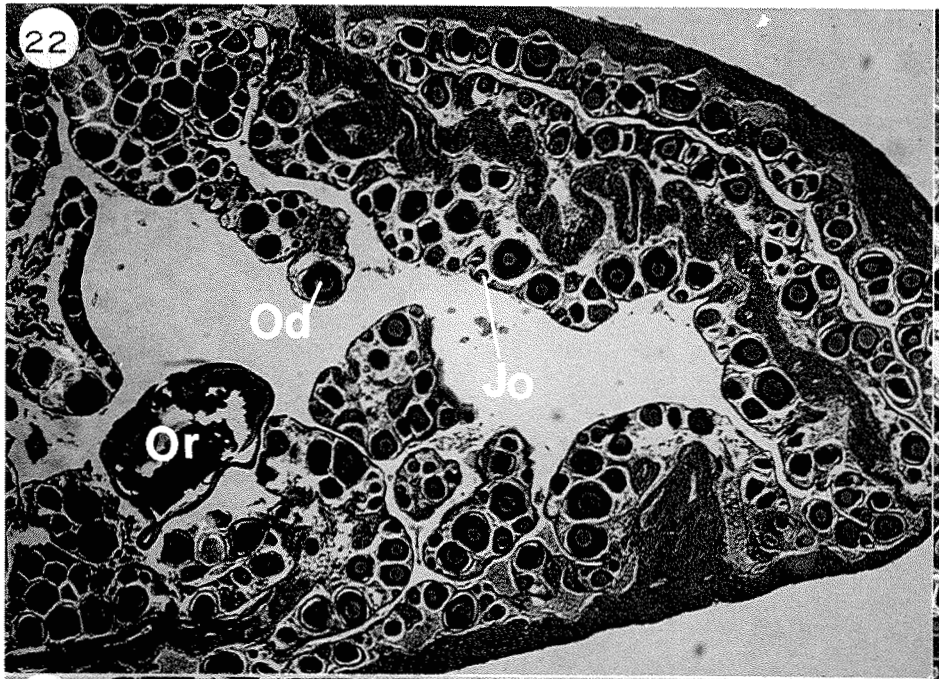

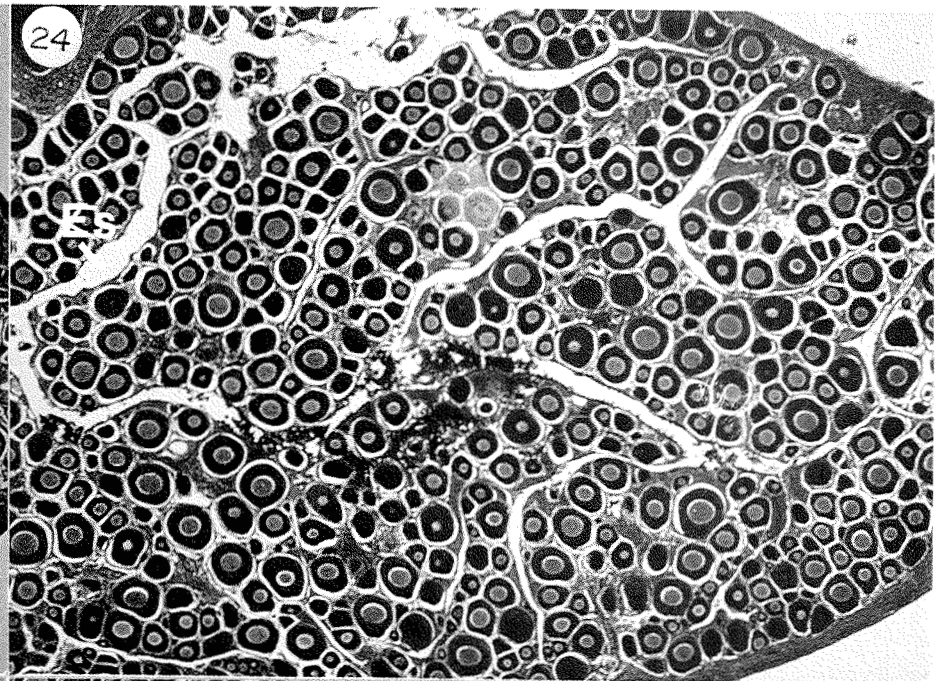

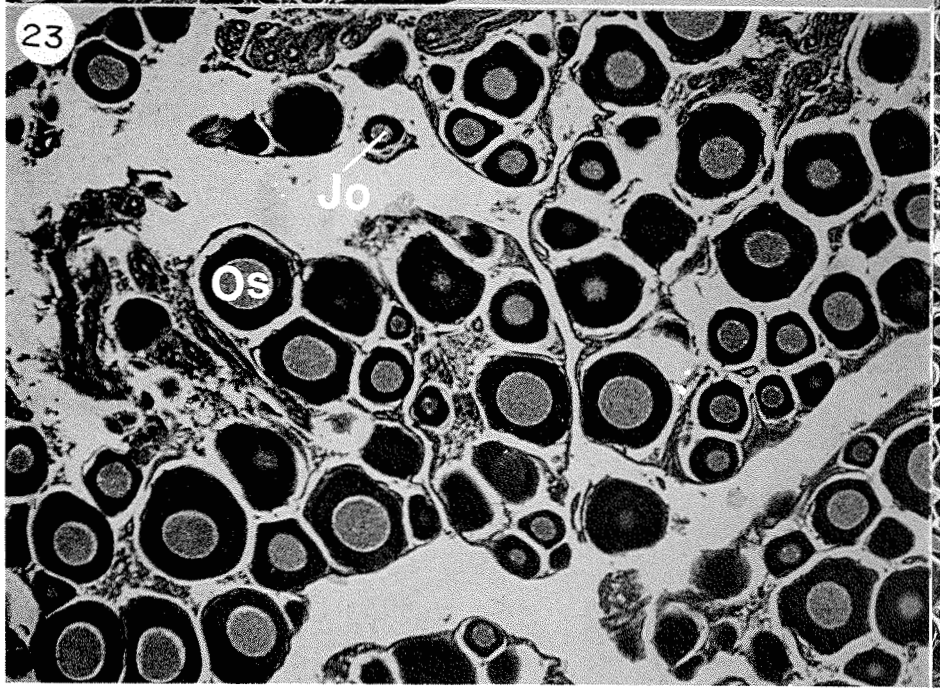

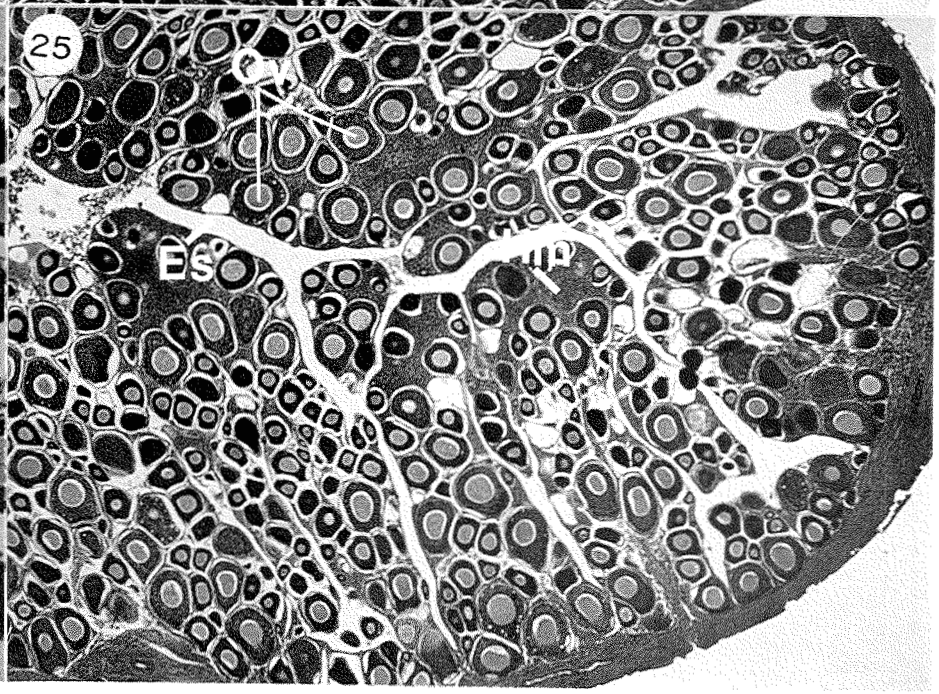

PLANCHE VII

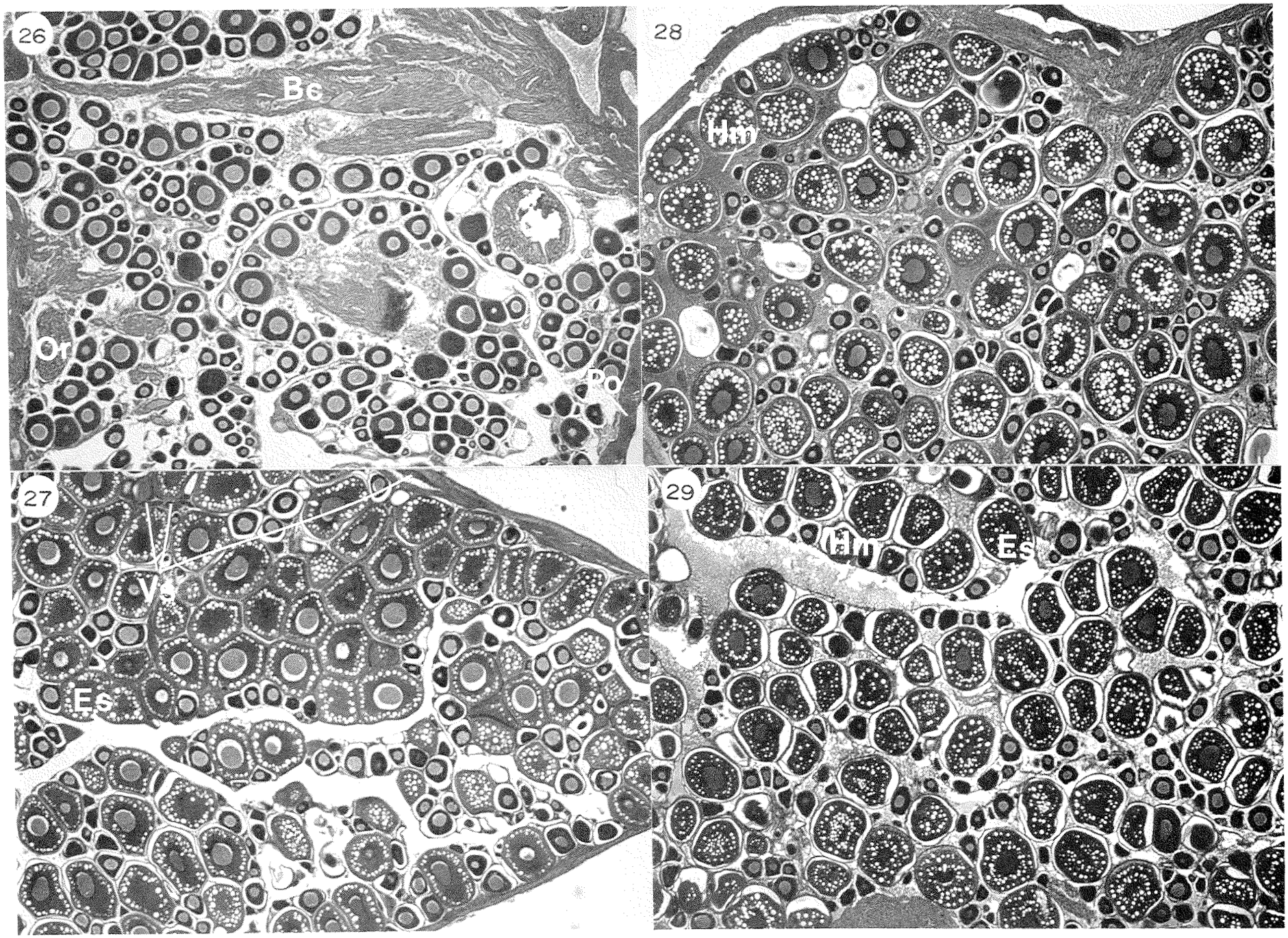

PLANCHE VIII

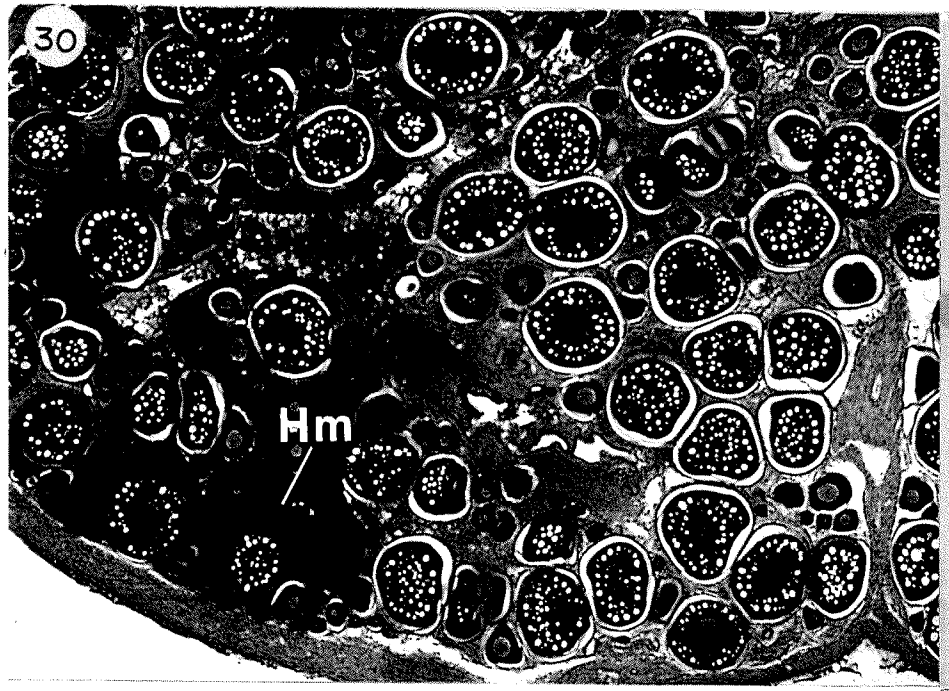





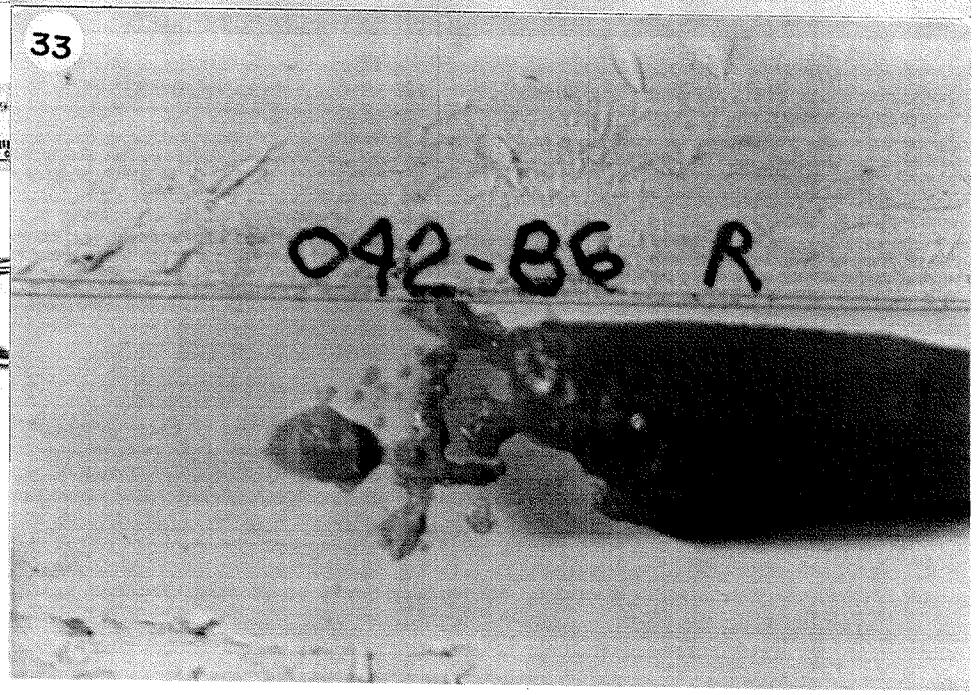

PLANCHE IX

34



36

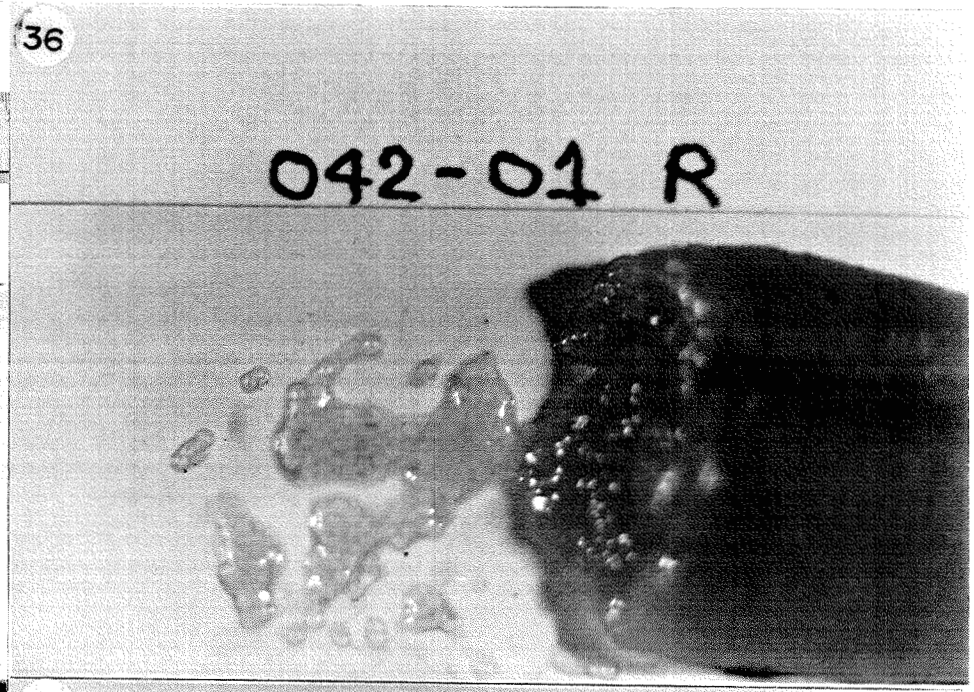

35



37



PLANCHE X

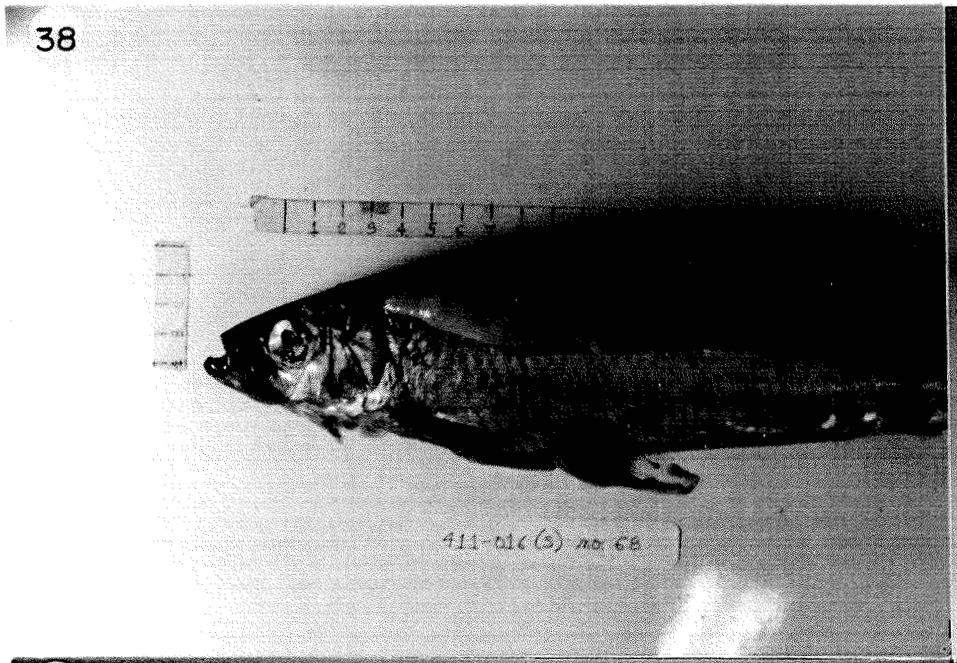







PLANCHE XI

42



44

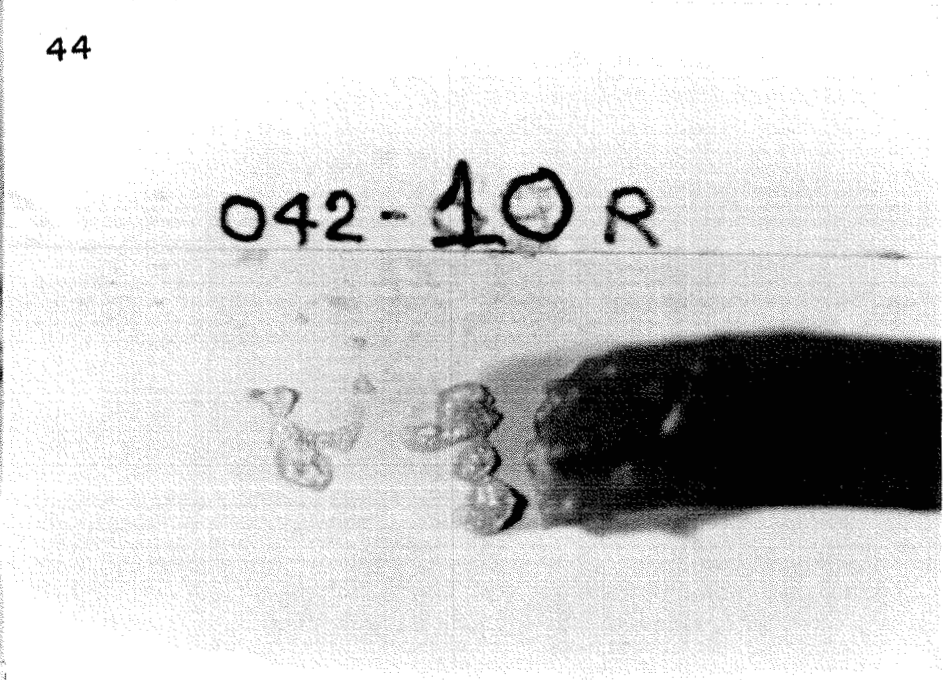

43



45



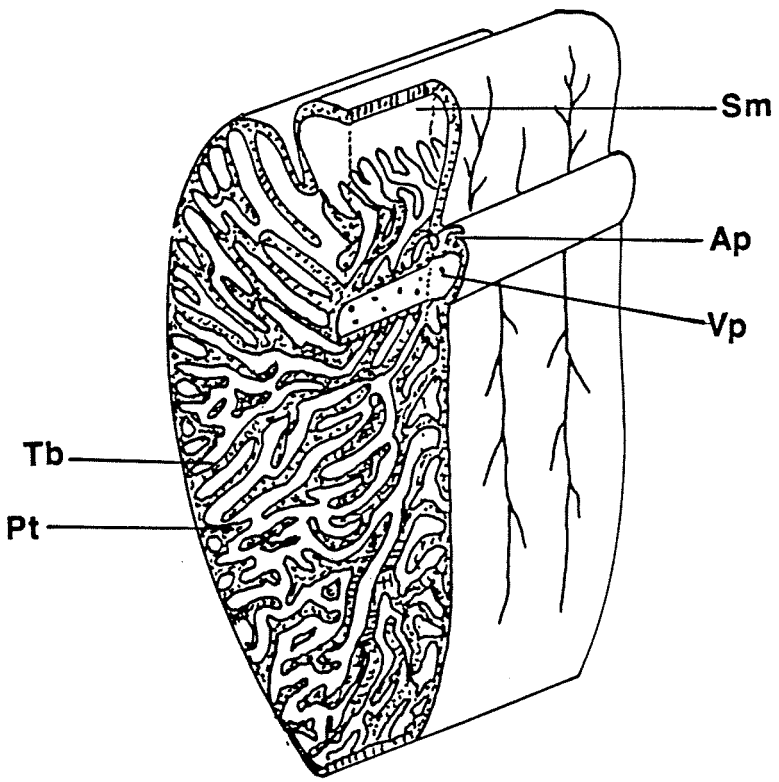

Figure 46 Schematic representation of testicular infrastructure, following completion of development. The testis consists of a wall from which ramifications of connective tissue extend to form the walls of the seminiferous tubules. The latter form a network of channels, all leading into the sperm duct, the channel through which sperm is discharged during spawning. The vascular system consists in part of one primary vein and artery, running the full length of the gonad (after Polder, 1961).

PLANCHE XII

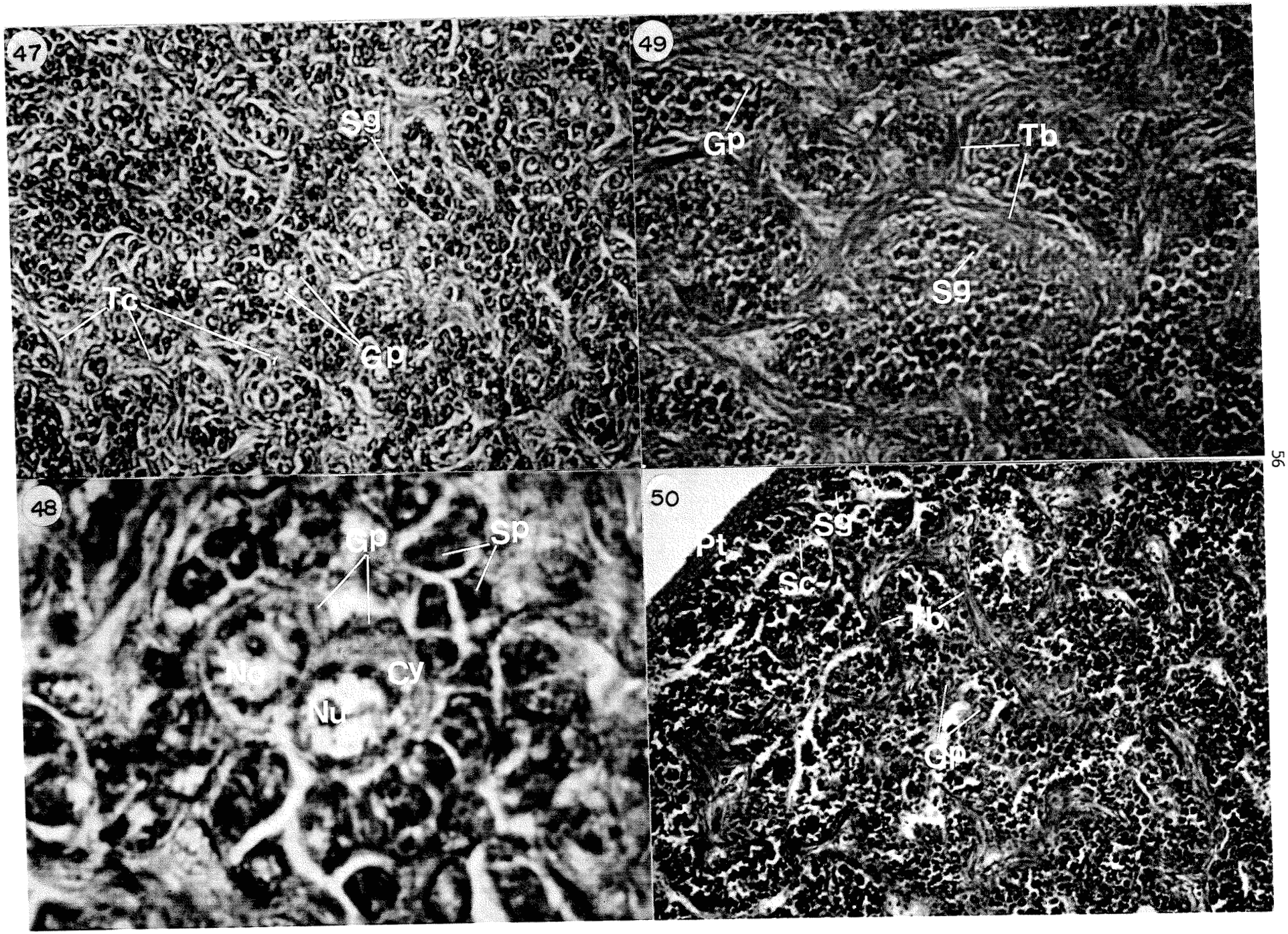

PLANCHE XIII

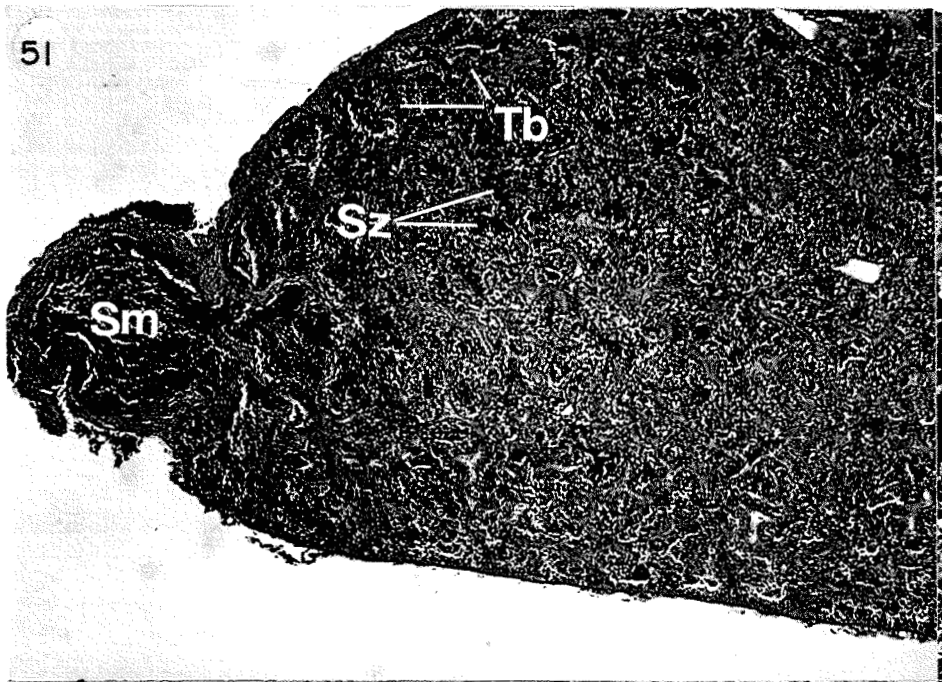



PLANCHE XIV

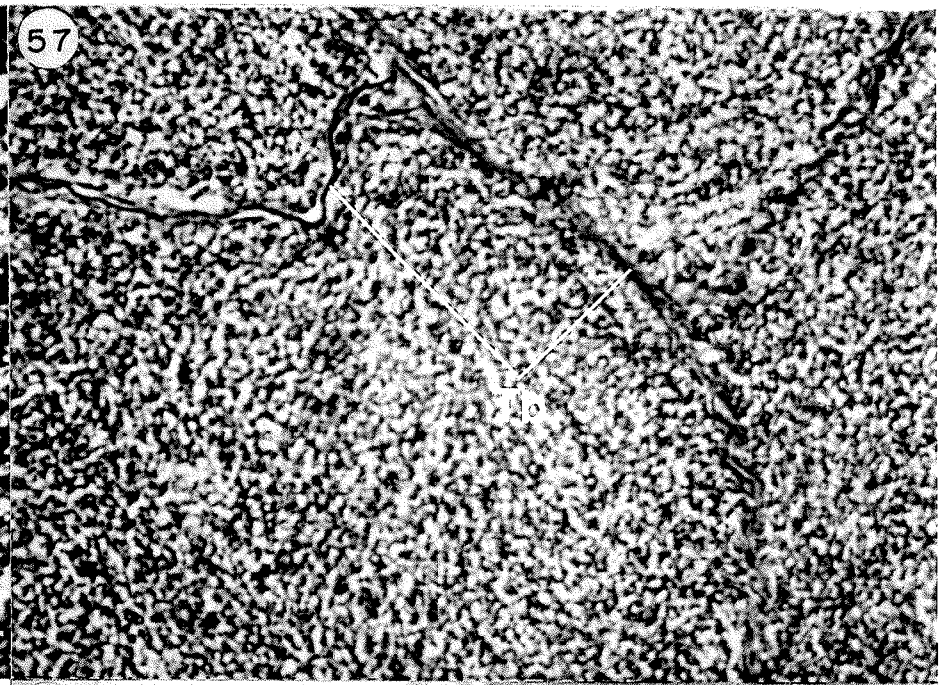

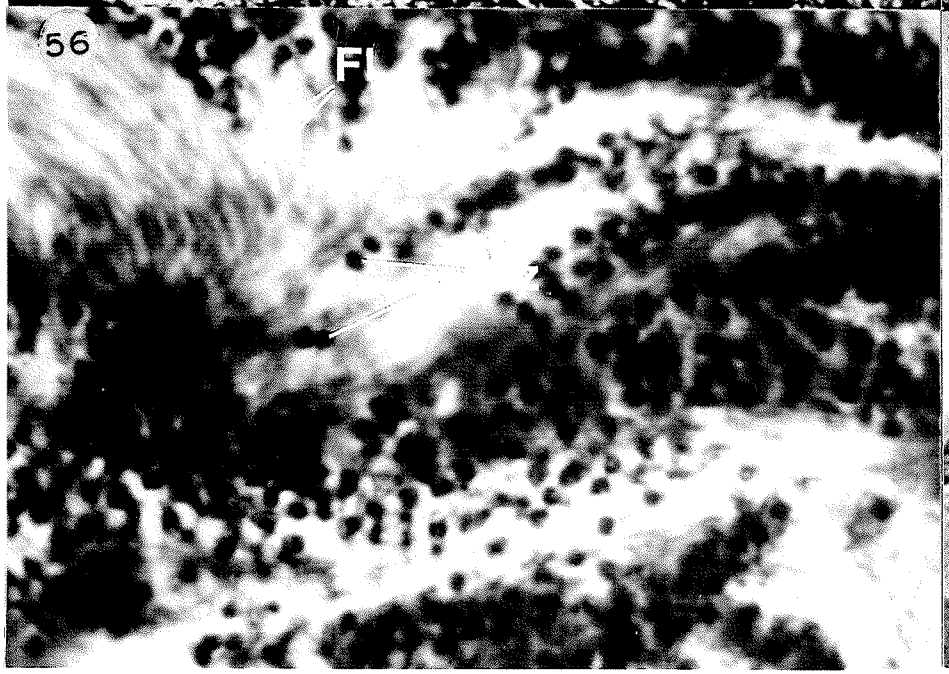

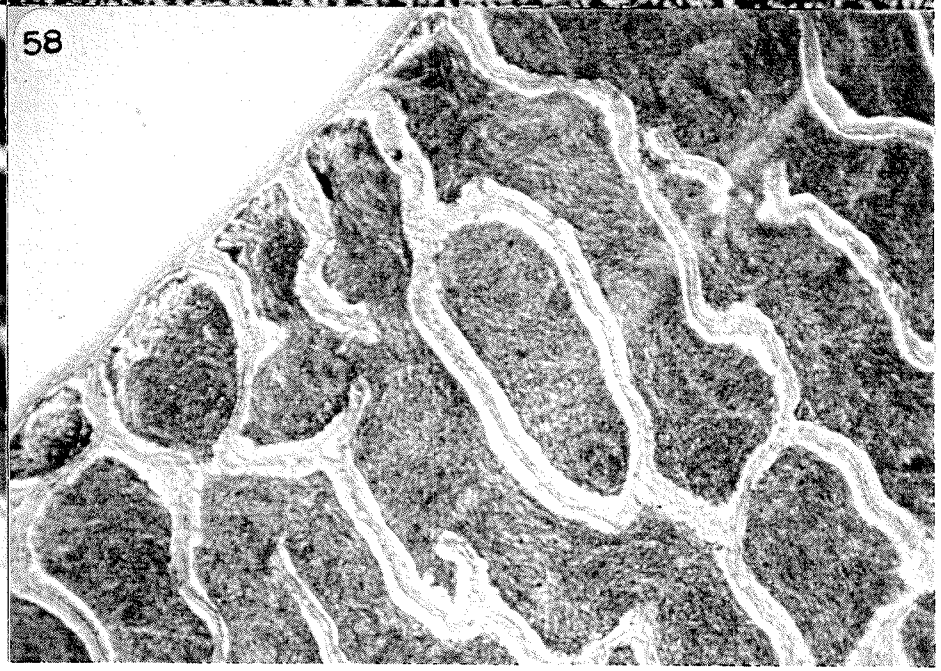

PLANCHE XV

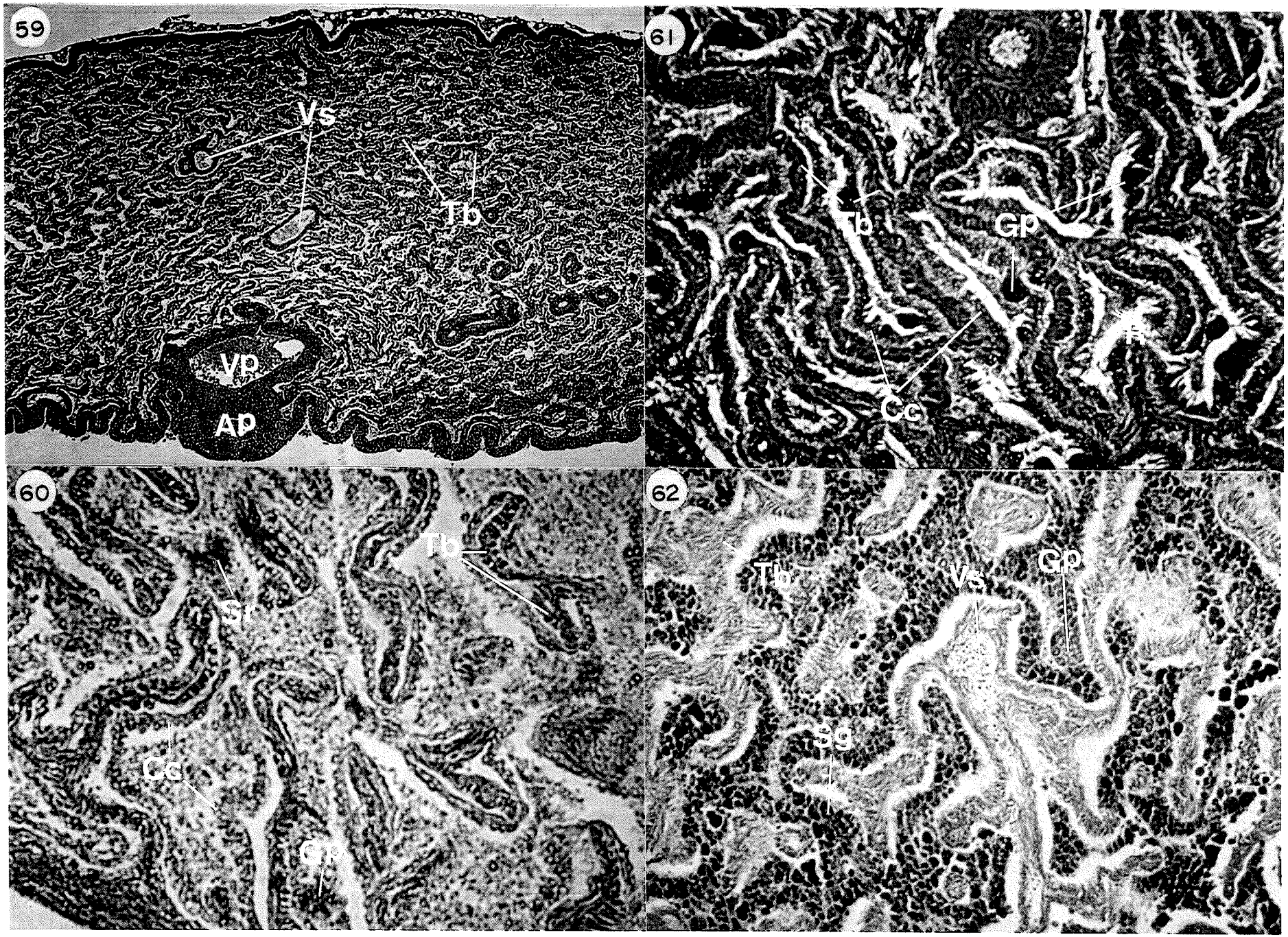

PLANCHE XVI

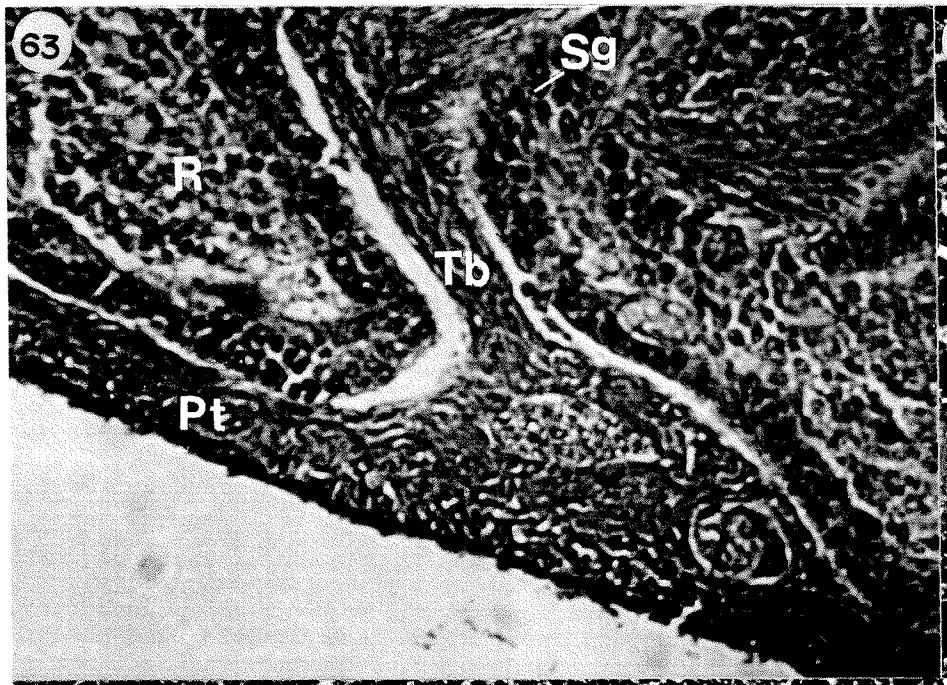

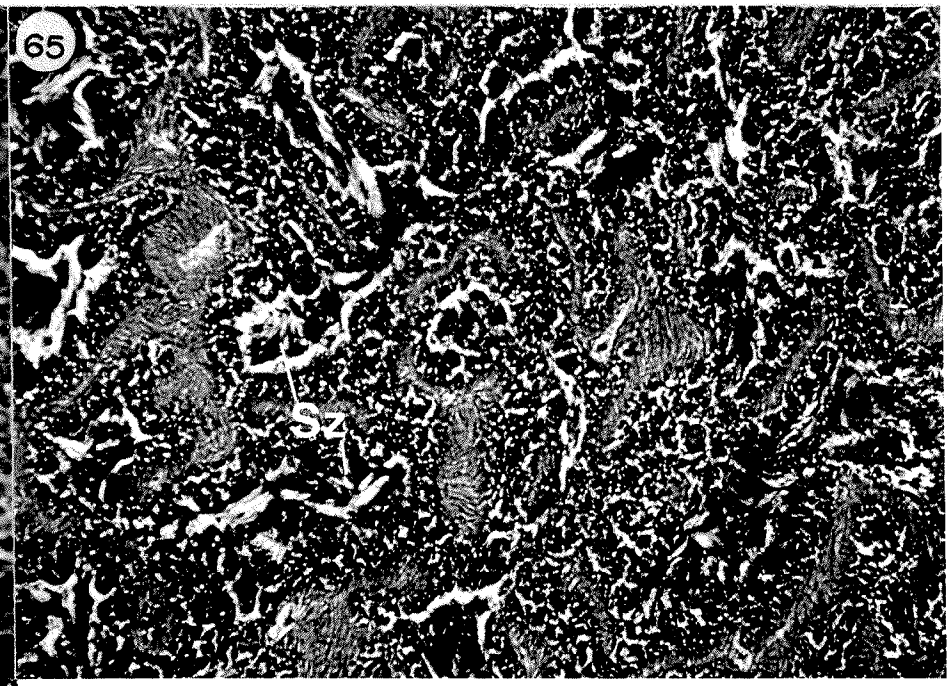

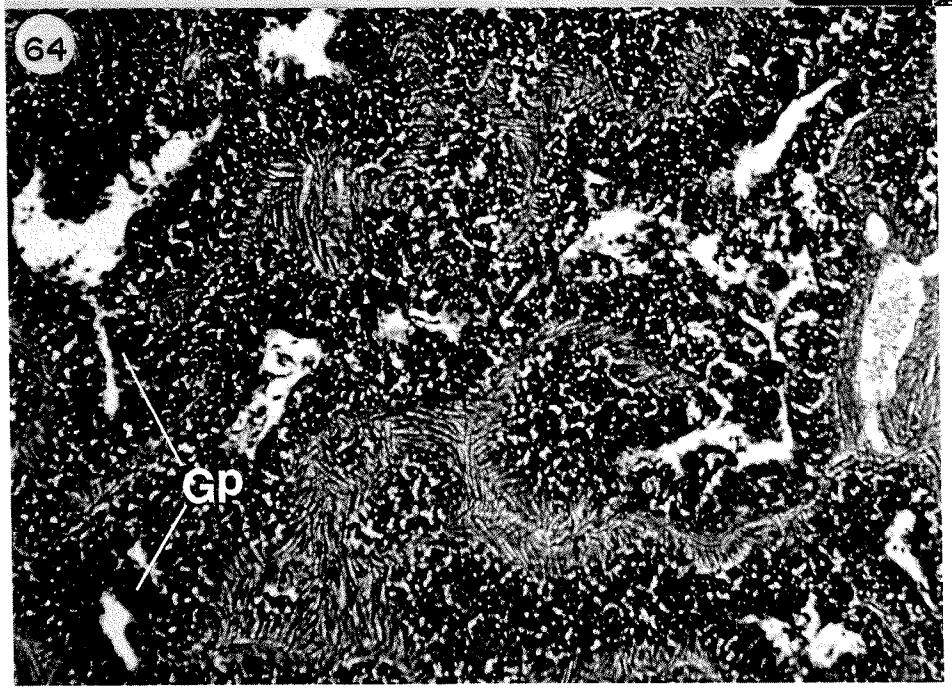

PLANCHE XVII

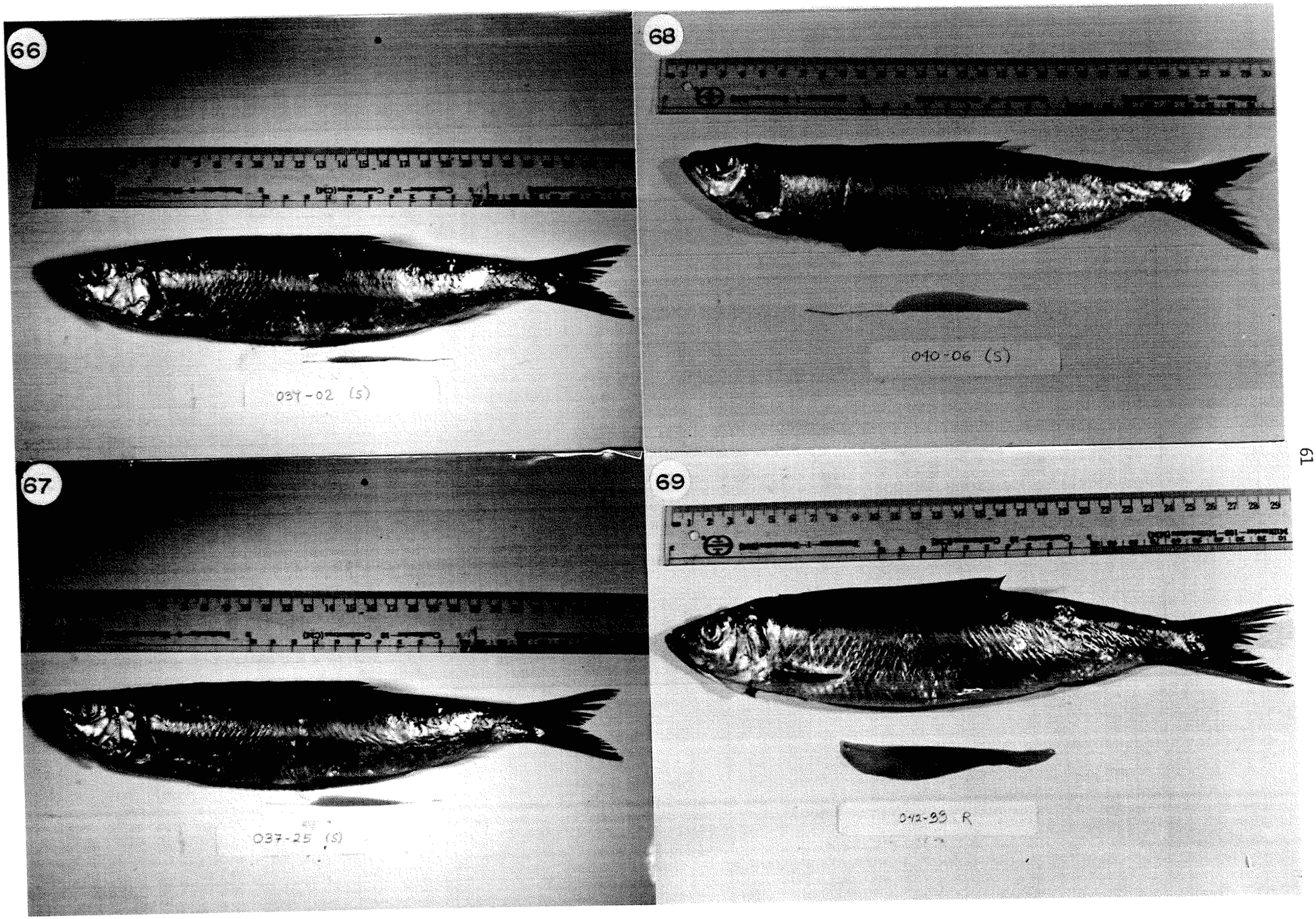

PLANCHE XVIII

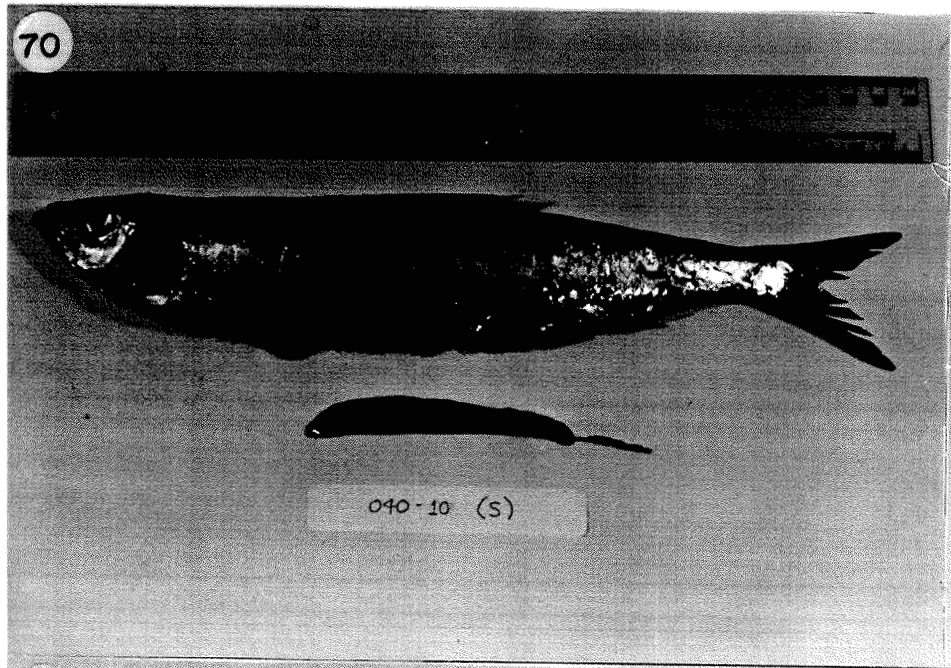

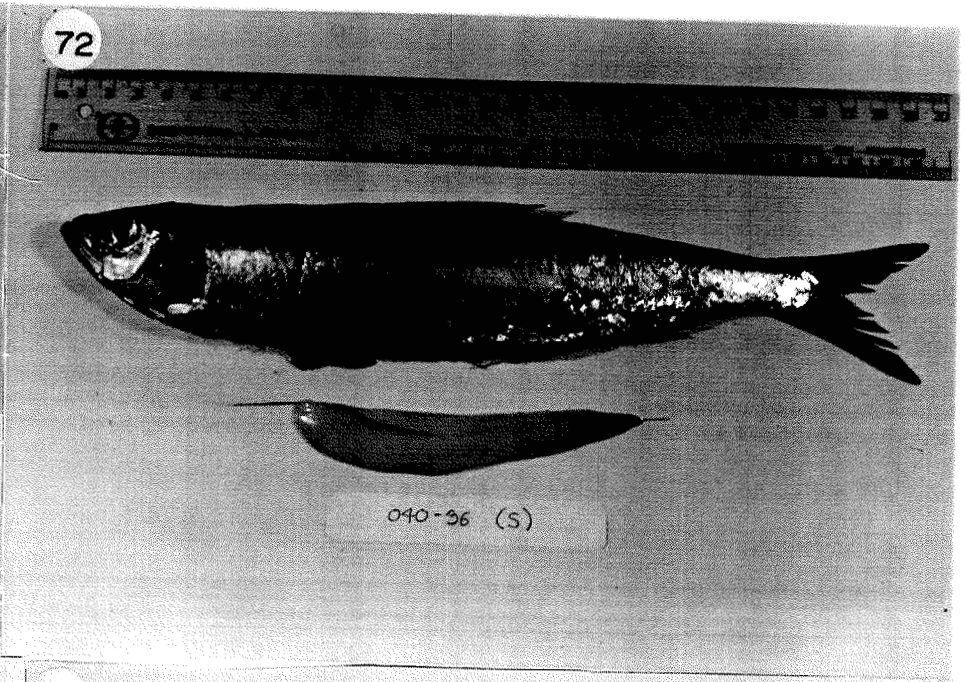



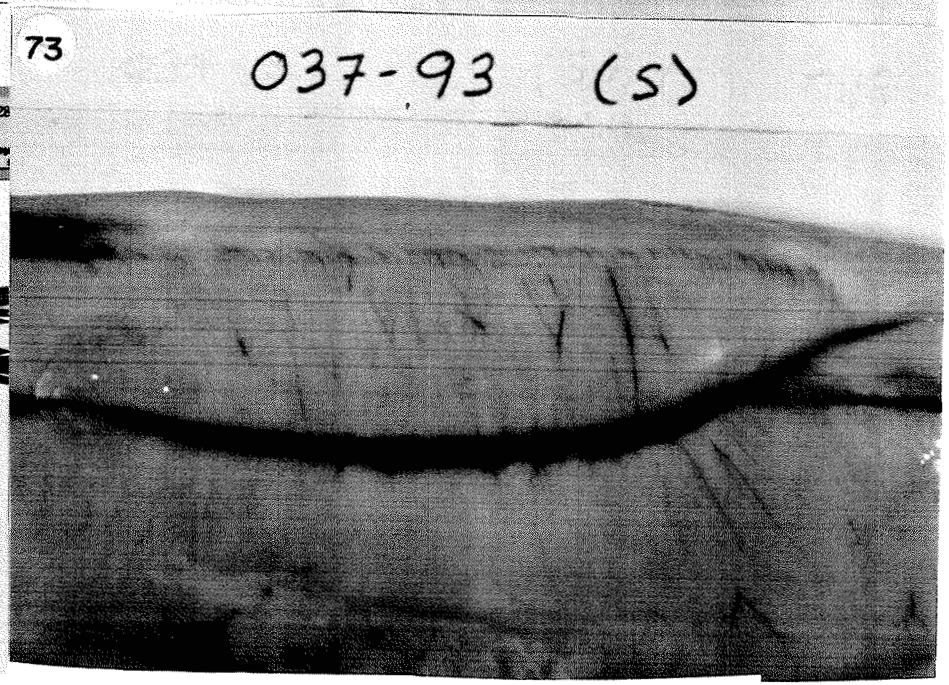

PLANCHE XIX







APPENDIX 1

MATURITY SCALE RECOMMENDED BY HERRING COMMITTEE OF ICES AND COMMENTS (*) GIVEN BY THE PARTICIPANTS OF THE ST JOHN'S AGING WORKSHOP (from Cleary et al., 1982).

Males

Stage

I Virgin herring. Testes very small, thread-like, whitish or grey-brown.
* Assignment of sex generally requires microscopic examination.

II Virgin herring with small sexual organs. Width of testes about 3-8 mm and reddish grey in colour.
* At stage 2 gonads are clearly visible and can be sexed according to the morphology of the gonad.

III Testes occupying about half of ventral cavity. Width of testes between 1 and 2 cm. Reddish grey or greyish.

IV Testes almost as long as body cavity. Testes whitish.

V Testes fill body cavity, testes milky white. Sperm do not flow but can be extruded by pressure.
* For stages III, IV and V with frozen fish, size of the gonads in relation to body cavity is the determinant character. There is a potential application for relative gonad weight.

VI Testes ripe, testes white and sperm flowing freely.
* At this stage, stress-induced extrusion of sexual product can occur. Initial analysis suggests that freezing may substantially reduce the incidence of free-flowing attribute of this stage.

VII Spent herring. Testes bloodshot but may contain remains of sperm.

VIII Recovering spents. Testes firm and larger than virgin herring in stage II. Walls of testes striated: blood vessels prominent, testes wine red in colour (this stage passes into stage III).
* Differentiation between stage II and VIII is difficult. In general, gonads at stage VIII are smaller and blood vessels are more prominent. However, on the basis of the present description, the transition period from VIII to III is not clearly defined. Since this is the major problem encountered in maturity designation, it is the area that should be examined more intensively. This problem might be resolved by relating histological analysis to some relative index of gonad weight.

APPENDIX 1 (continued)

Females

Stage

I Virgin herring. Gonads very small, 2-3 mm broad, ovaries wine red.

II Virgin herring with small sexual organs. Width of ovaries about 3-8 mm, eggs not visible to naked eye but can be seen with a magnifying glass.

III Ovaries occupying about half of ventral cavity, width of ovaries between 1 and 2 cm. Eggs small but can be distinguished with naked eye, orange in colour.

IV Ovaries almost as long as body cavity. Eggs larger, varying in size, opaque, orange or pale orange.

V Ovaries fill body cavity. Yellowish in colour. Eggs large, round; some transparent but do not flow.
* Size and visibility of the eggs is the determinant criterion between these stages.

VI Ovaries ripe. Eggs transparent and flowing freely.

VII Spent herring. Ovaries baggy and bloodshot, empty or containing only a few residual eggs.

VIII Recovering spents. Ovaries firm and larger than virgin herring in stage II. Eggs not visible to naked eye. Walls of ovary striated, blood vessels prominent, ovaries wine red in colour (this stage passes into stage III).

APPENDIX 2

HISTOLOGICAL CRITERIA DEFINING EACH MATURITY STAGE

A - Females

Stages I and II: virgin herring

I - Organization of the connective tissue and of the vascular system and production of a line of germ cells occur in the ovary. The oocyte maturation phase has not yet begun. The oocytes are dark in colour, contain no yolk and the theca is the only follicular layer. In longitudinal section, the ovary shows a very pronounced lamellar structure.

IIa - Beginning of the oocyte maturation phase. The cytoplasm is lighter in colour than in stage I and the presence of yolk vesicles may be noted.

IIb - The first yolk globules appear, but are present in very small numbers and located around the periphery of the oocytes.

Stages III to V: rapid gonad growth phase

IIIa - The yolk vesicles occupy up to half the cytoplasm of the oocytes, the portion around the periphery. In most of the oocytes, the portion of the cytoplasm adjacent to the nucleus contains no yolk globules.

IIIb - The globules have invaded the portion of the oocyte cytoplasm adjacent to the nucleus, but in most of the cells, the nucleus is clear of yolk globules.

IV - The globules are pressed around the nuclear membrane and may even infiltrate the nucleus. Generally, the yolk vesicles form only a narrow band around the periphery of the oocytes.

V - Decentralization of the nucleus begins. By the end of stage V, the nucleus has completely disappeared and the yolk globules have become very large (by fusion). The oocytes are still surrounded by their follicles.

APPENDIX 2 (continued)

Stage VI: spawning

VI - Ovulation occurs. The mature eggs are located in the central portion of the ovary, with the empty follicles and resting oocytes around the periphery. The number of eggs decreases as spawning progresses.

Stages VII and VIII: reconstruction phase

VII - The ovary is almost completely empty of its egg content. The few mature eggs still present are considered to be on the point of resorption. The young oocytes present in the ovary have the same characteristics as those in stage I. The distinction from stage I must be based on spawning marks present in stage VII. These may be:

(a) empty follicles;
(b) mature eggs not discharged during spawning;
(c) thickening and contortions of the connective tissue;
(d) absence of lamellar structure throughout the gonad, or, at least, in its central portion;
(e) hematomas;
(f) prominent blood vessels.

VIIIa - Beginning of the oocyte maturation phase. The cytoplasm of the oocytes is lighter in colour, but they contain no yolk.

VIIIb - Yolk vesicle production phase.

VIIIc - Appearance of the first yolk globules, although they are still present only in small numbers and form only a narrow band around the periphery of the oocytes.

Stage VIII corresponds to stage II, in terms of germ cell development. The distinction between these two stages is linked to the presence of spawning marks in stage VIII. In stage VIIIa, these marks are the same as in stage VII, with the exception of the lamellar structure, which may already be partially reconstructed, and the empty follicles, which have generally been completely resorbed. In stages VIIIb and VIIIc, the only observable spawning marks are:

(a) thickening and contortions of the connective tissue;
(b) presence of prominent blood vessels or hematomas;
(c) presence of mature eggs not discharged during the previous spawning;
(d) spacing between the connective tissue lamallae.

The spawning marks may become very difficult to detect, as stage VIII progresses. The ovary then passes into stage III.

APPENDIX 2 (continued)

B - Males

Stages I and II: virgin herring

I - Organization of the connective tissue and of the vascular system and production of an initial group of spermatogonia occur in the testis. By the end of stage I, spermatogonia are more numerous than primary germ cells. The connective tissue is not yet organized into seminiferous tubules.

IIa - Spermatogenesis begins, but maturation has not advanced beyond the spermatogonium multiplication phase. The distinction from stage I is based on the larger proportion (arbitrarily determined) of spermatogonia in stage II. Generally, the primary germ cells are restricted to small isolated groups, while spermatogonia occupy the rest of the seminiferous tubules.

IIb - The spermatogonia pass into the other stages of the spermatogenic cycle. By the end of stage II, the testis contains all germ cell maturation phases (primary germ cells, spermatogonia, primary and secondary spermatocytes and spermatozoa). However, spermatozoa are present only in small numbers and in only a few of the seminiferous tubules.

Stages III to V: rapid gonad growth phase

III - Distinguished from stage II by the presence of spermatozoa in the majority of the seminiferous tubules. Spermatozoa occupy no more than one third of the area defined by the seminiferous tubules.

IV - Spermatozoa occupy between one third and 3/5 of the area defined by the seminiferous tubules.

Va - Only a narrow band of spermatocytes remains around the periphery of the seminiferous tubules. Later, the testis contains only spermatozoa, but they continue to resemble dense packets of nuclei.

Vb - The spermatozoa have become detached from the Sertoli cells and are now evenly distributed through the seminiferous tubules.

APPENDIX 2 (continued)

Stage VI: spawning

VI - The testis is classified in stage VI when the contents of the seminiferous tubules begin to show some loosening from the walls. Stage VI is typically represented, however, by the absence of sperm from a number of tubules.

Stages VII and VIII: reconstruction phase

VII - The majority of the seminiferous tubules are empty of their sperm content. Small groups of primary germ cells can be identified in a few seminiferous tubules. The distinction from stage I is based on the following spawning marks:

(a) presence of residual sperm;
(b) thickening and contortions of the testicular and tubule walls;
(c) structure of the seminiferous tubules, which is largely or entirely indefined;
(d) presence of prominent blood vessels and occasionally hematomas.

VIIIa - The primary germ cells continue the division process. The spermatogonia undergo extensive multiplication, thus increasing considerably in number in the seminiferous tubules. The other stages of the spermatogenic cycle, however, are not yet present.

VIIIb - Presence of all phases of germ cell development; spermatozoa, however, are present only in small numbers and can be observed in only a few of the seminiferous tubules.

Stage VIII is similar to stage II, in terms of germ cell development. The only difference lies in the area of spermatogonium production, which is already advanced when the testis passes into stage II, whereas it is just beginning in stage VIIIa. The distinction between these two stages must thus be based as well on the spawning marks visible in stage VIII. In stage VIIIa, these marks are the same as in stage VII, except that resorption of the residual sperm is more advanced and that contraction of the tubule walls is more evident. In stage VIIIb, resorption of the residual sperm is generally completed. The signs of spawning are then indicated primarily by the contraction of the tubule walls and occasionally by the presence of a more fully developed vascular system (presence of prominent blood vessels and occasionally hematomas).

APPENDIX 3

LIST OF MACROSCOPIC CRITERIA TO BE GIVEN PRIORITY IN ASSIGNING MATURITY STAGE

Males

STAGE		
I	Width:	maximum 3 mm[1]
	Length:	up to 1/2[2]
II	Width:	3 to 8 mm[1]
	Length:	1/2 to 2/3[2]
III	Width:	5 to 10 mm (posterior end) and 10 to 20 mm (widest point)[1]
	Length:	2/3 or more[2]
IV	Width:	may exceed 10 mm (posterior end) and 20 mm (widest point)[1]
	Length:	generally entire cavity
V	Volume:	100% of the cavity
	Sperm duct:	swollen over entire length[5]
	Colour:	generally milky white[7]
VI	Sperm duct:	very dilated
	Testes:	more viscous[8]
VII	Gonads	flaccid, bloodshot (brownish) and generally empty [5]
VIII	Firmer than in stage VII. Wine red tints and more elongated in shape than in stage II[11]. Testes larger than in stage II[12], but narrower than in stage III[13].	

Females

STAGE		
I	Width:	maximum 3 mm[1]
	Length:	up to 1/2[2]
II	Eggs:	difficult to see with the naked eye[3]
	Width:	3 to 8 mm[1]
	Length:	1/2 to 2/3[2]
III	Eggs:	readily visible to the naked eye
	Width:	5 to 10 mm (posterior end) and 10 to 20 mm (widest point)[1]
	Length	:2/3 or more[2]
IV	Width:	may exceed 10 mm (posterior end) and 20 mm (widest point)[1]
	Length:	generally entire cavity
	Eggs:	opaque[4]
V	Volume:	100% of the cavity
	Eggs:	some are transparent[6]
VI	Eggs:	all transparent
	Ovary:	separates into lamellae
VII	Gonads flaccid, bloodshot (wine red) and generally empty[5]	
VIII	Cylindrical[10] and firmer than in stage VII. Wine red tints and more elongated than in stage II[11]. Testis wider than in stage II[12].	
	Eggs:	difficult to see with the naked eye[3]

APPENDIX 3 (CONTINUED)

(1) Gonad width values are given merely to provide some idea of their approximate size at the different maturity stages. These values do not reflect variations related to fish size.

(2) Expressed in terms of the length of the body cavity.

(3) In females, the visibility of the eggs to the naked eye represents the best criterion for separating stages II (or VIII) and III.

(4) The eggs become opaque during stage III. However, this parameter may provide additional information for the identification of stage IV.

(5) Swelling of the sperm duct may also be observed in stage IV. Thus, the volume of the body cavity occupied by the gonads must be considered the priority characteristic for classification of stage V.

(6) The presence of a few transparent eggs is not regularly observed in stage V. The volume of the gonad in relation to that of the body cavity thus remains the priority criterion for distinguishing stages IV and V.

(7) The testis may also be pinkish grey. Colour alone cannot be used to identify this maturity stage.

(8) The viscous appearance of the gonads may vary, depending on the condition of the sample (Cleary et al., 1982).

(9) This characteristic may vary considerably, depending on the quantity of residues present in the gonad.

(10) The cylindrical appearance of the ovary may constitute the best parameter for distinguishing stages VII and VIII. This appearance is related to the production of a new line of oocytes and to the beginning of the maturation phase of some of them.

(11) This criterion is generally valid only for a gonad at the beginning of stage VIII.

(12) Towards the end of stage VIII, the width of the gonad, which is slightly greater than in stage VIII (5 to 10 mm, rather than 3 to 8 mm), is the only criterion which permits distinction from stage II, but the use of this parameter involves a very wide margin of error.

(13) In males, the distinction between stages VIII and III must be based solely on gonad width.